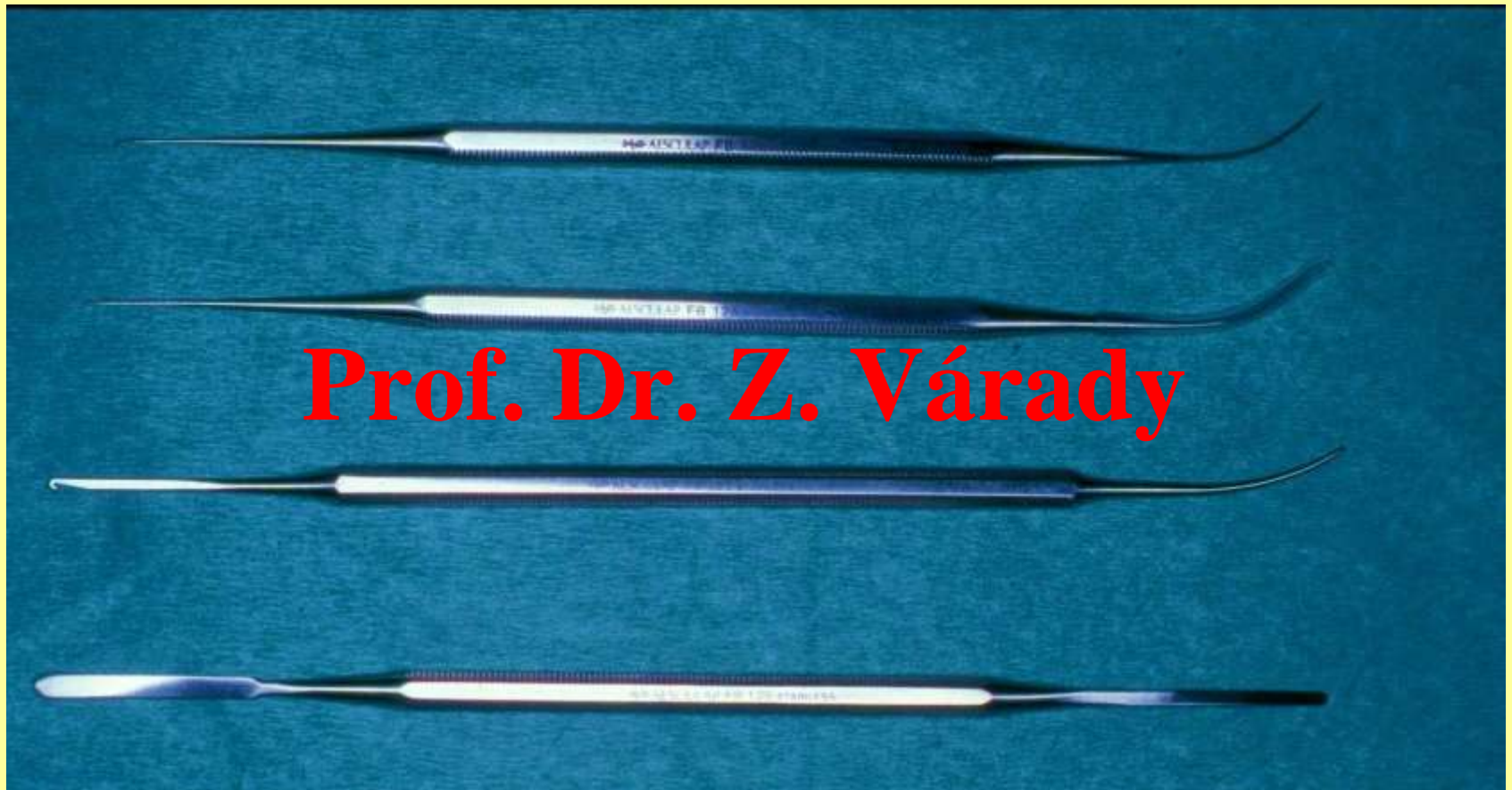
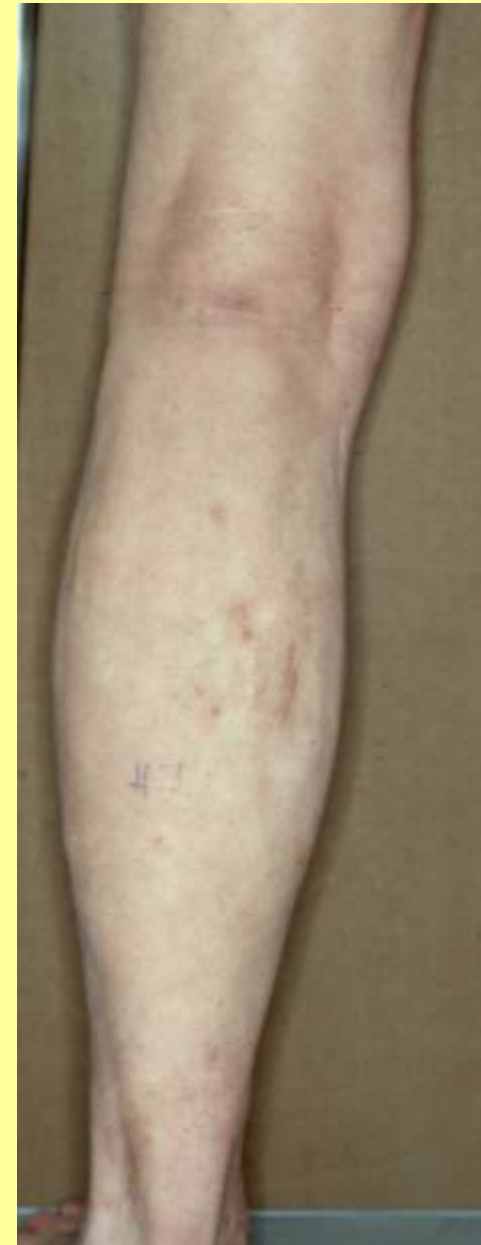
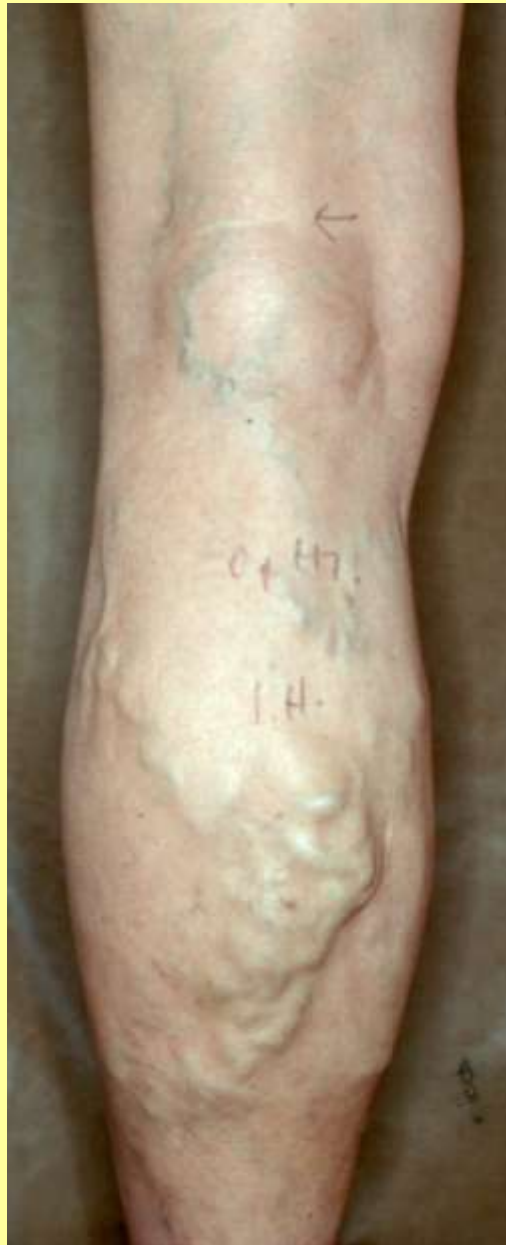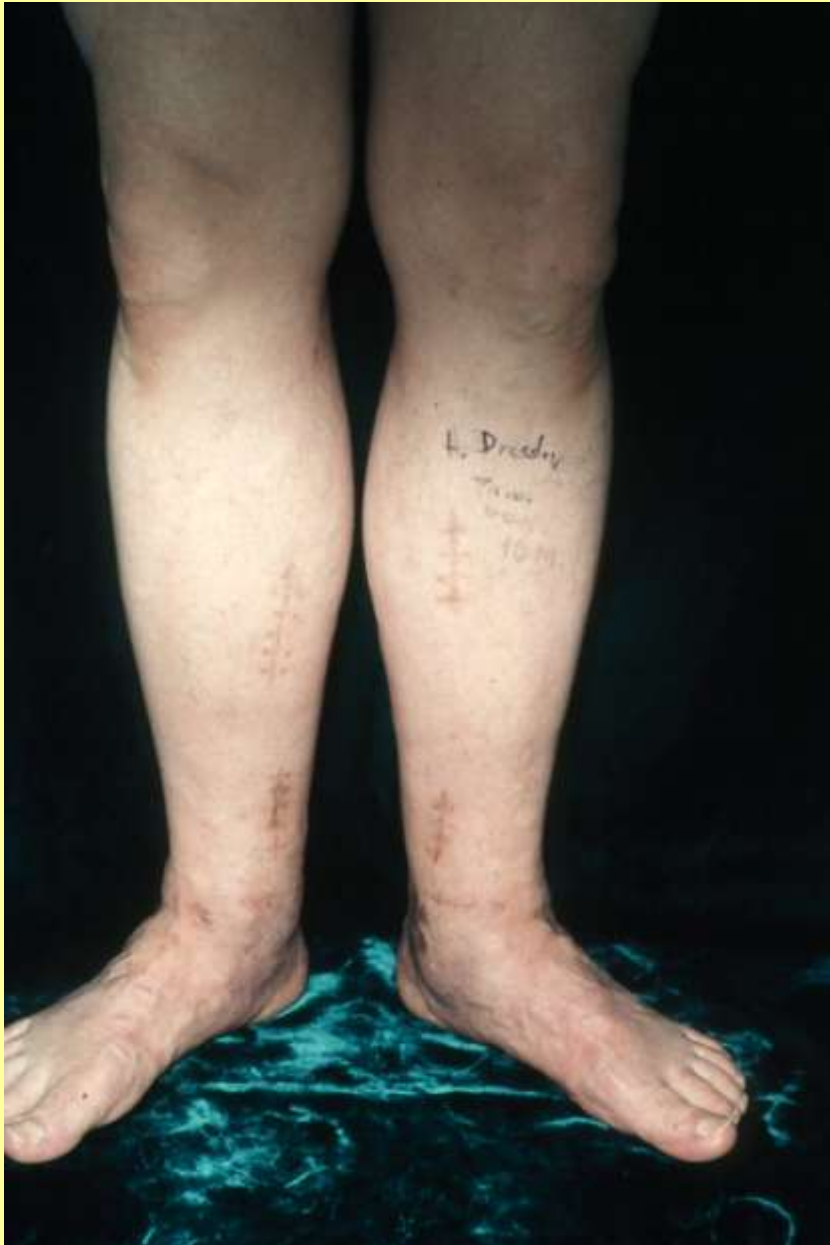Minisurgery Instruments of Varicose Veins acc.Várady

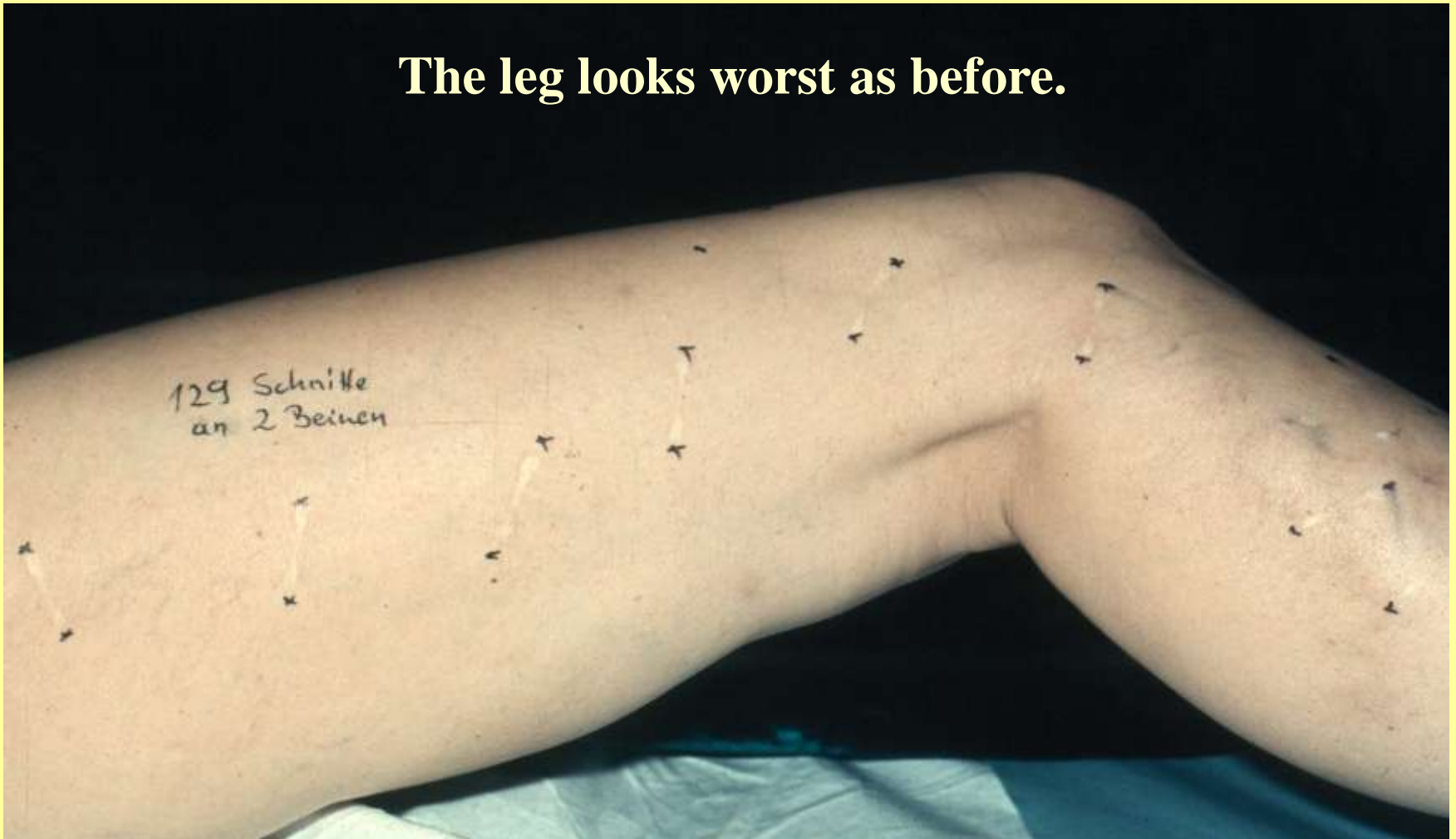

In many cases scars after **traditional surgery** are more annoying for the patient than varicose veins from before.

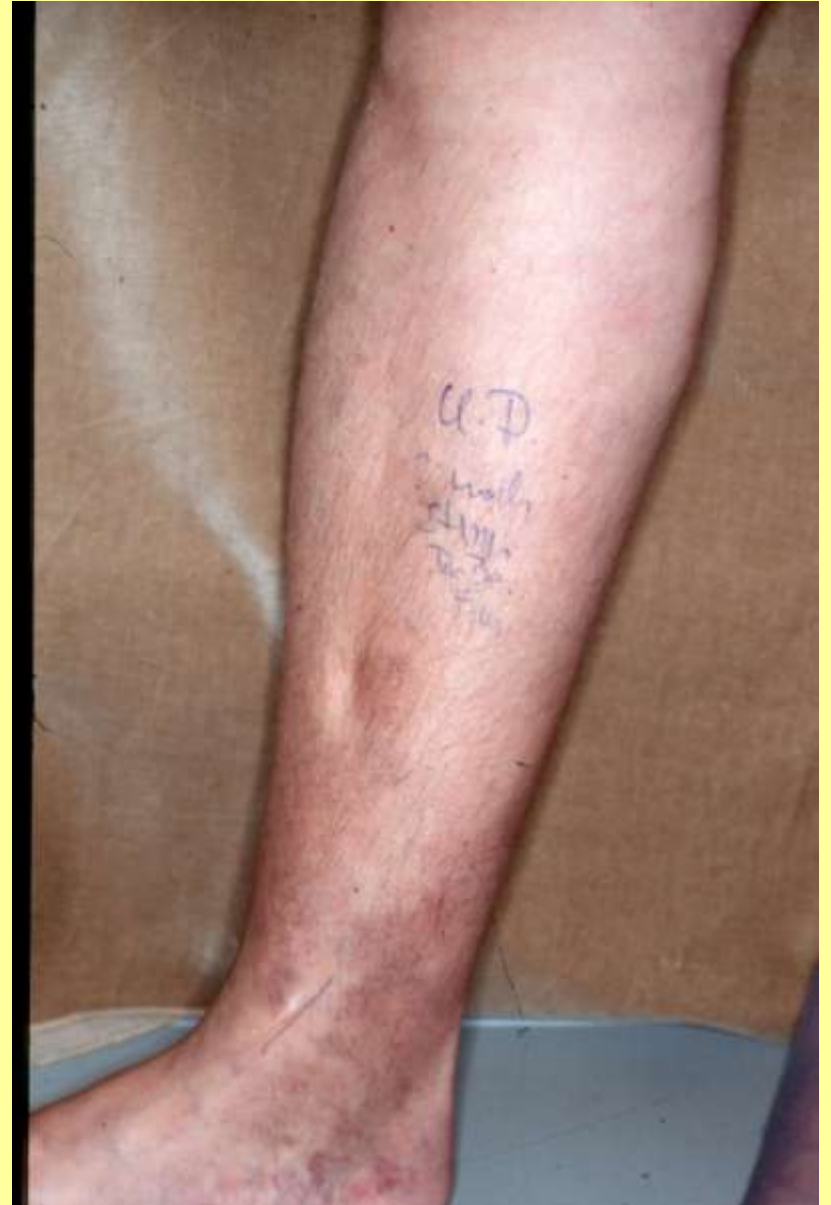
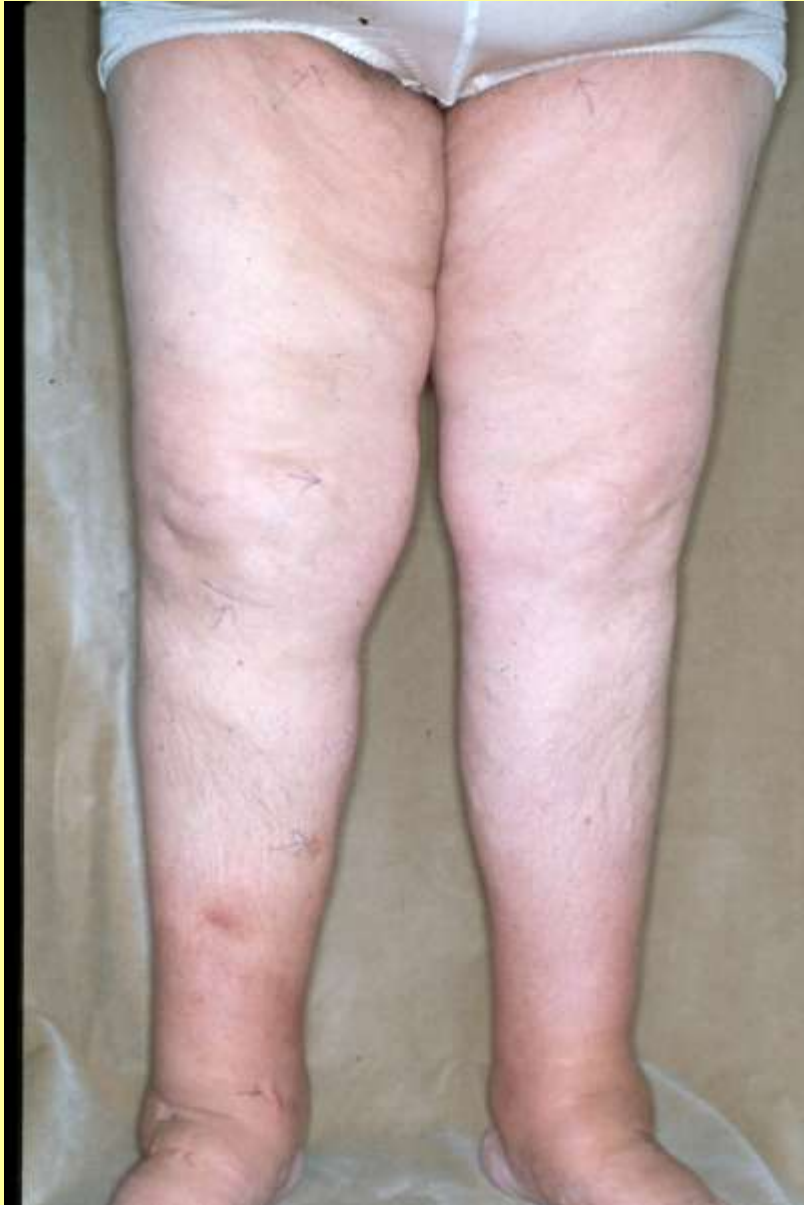
Oftentimes **stripping** is combined with more or less large
and numerous cuts to extract branches.

The leg looks worst as before.



After stripping and crossectomy besides that many develop **edema** because of the **destruction of lymphatic vessels**.



**In cases of oedema the traumatic
radical veinsurgery is strictly forbidden
according to leading Lymphologist**

Prof. Földi (Germany),

Prof. Cossio (Madrid),

Prof. Malan (Rio de Janeiro),

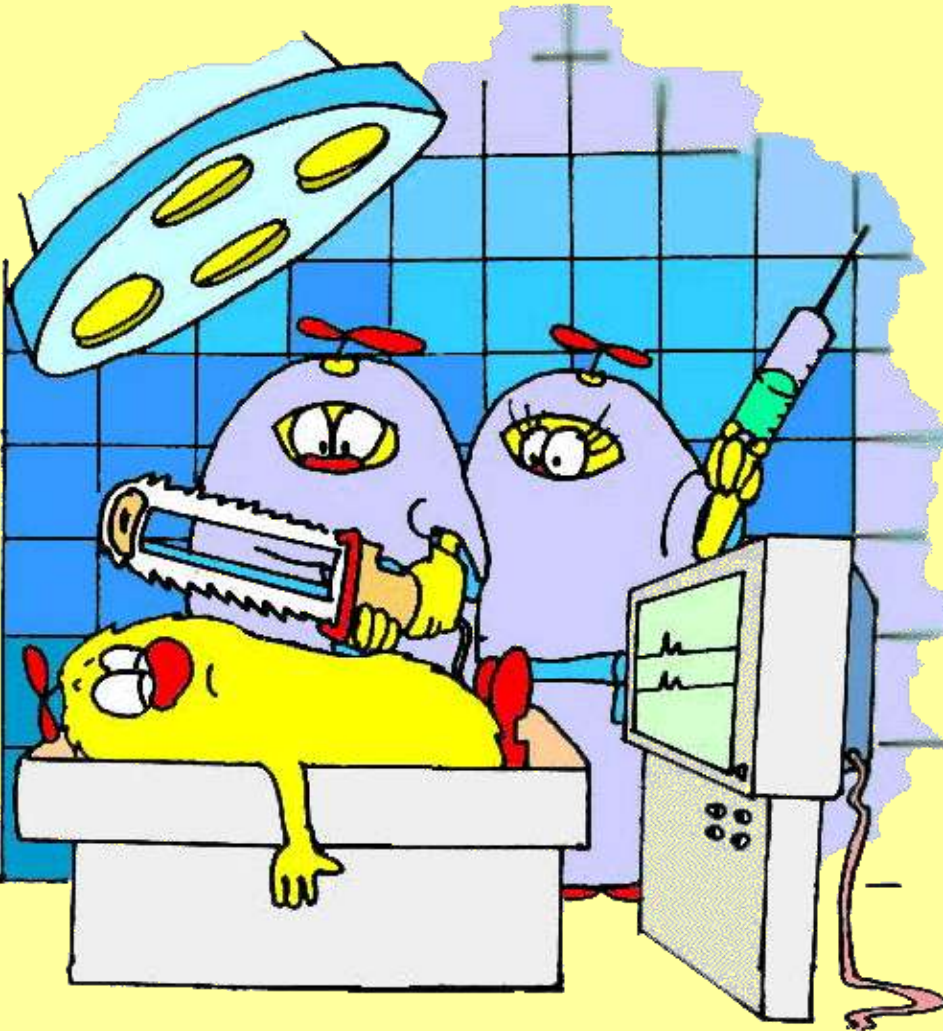
Prof. Degni (Sao Paulo) and others

only the Minisurgery acc. to

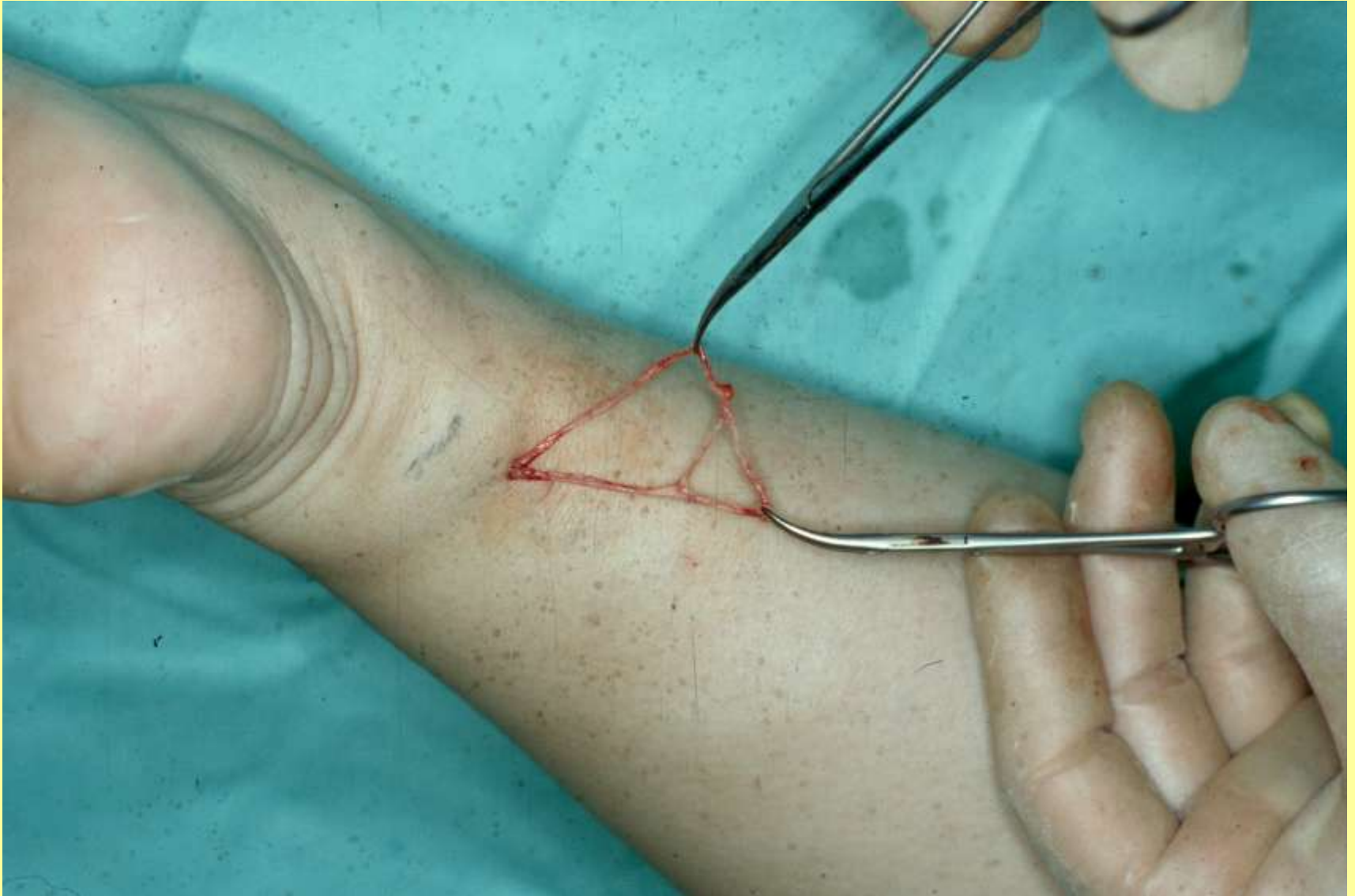Várady is recommended.

**You can often
ask yourself,
if a great
effort,**

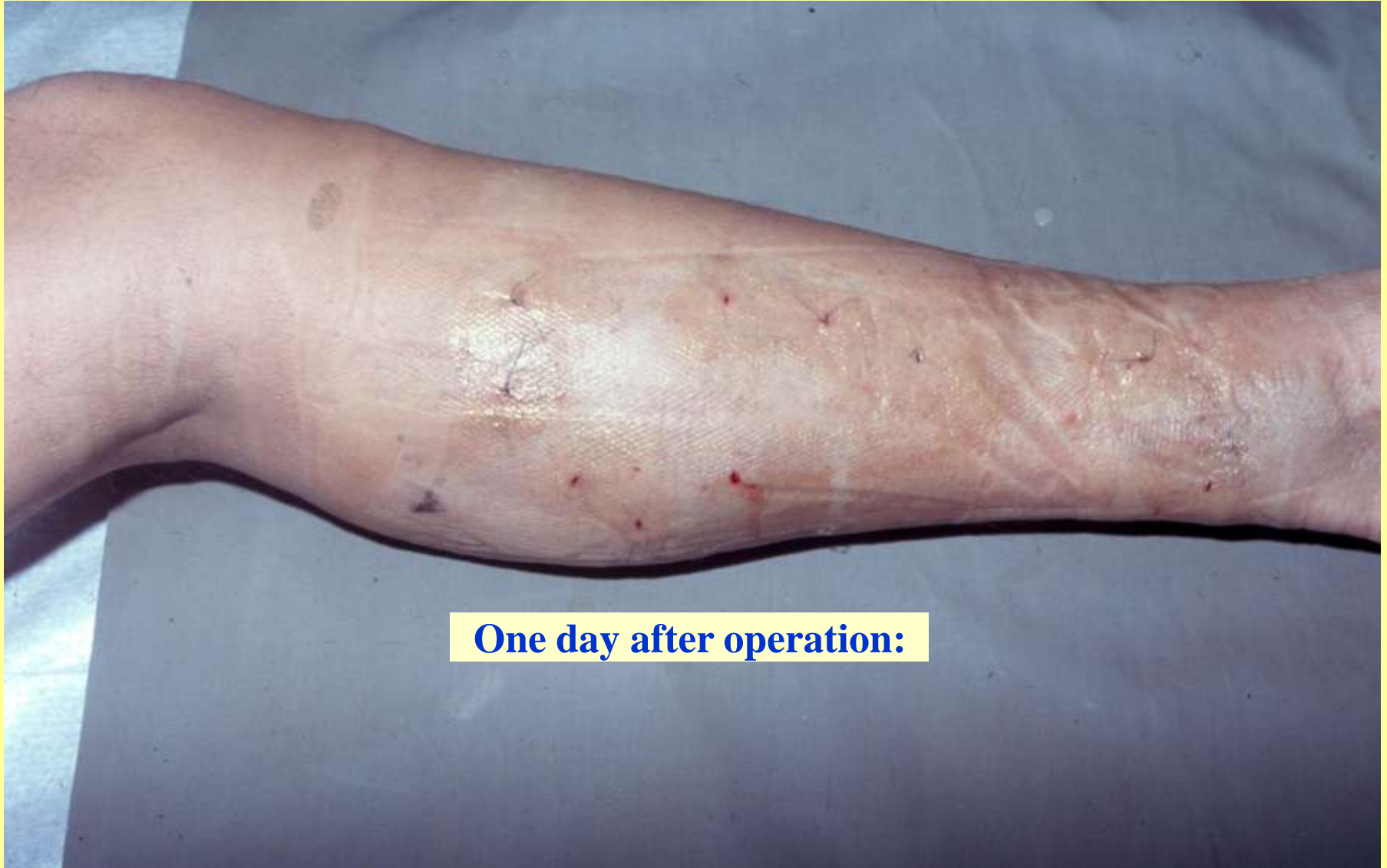**is really useful
for the medical
necessity and
the success.**



Therefore it is of the greatest importance to have one method in mind which contains both the **medical** and the **cosmetic** aspects as well.

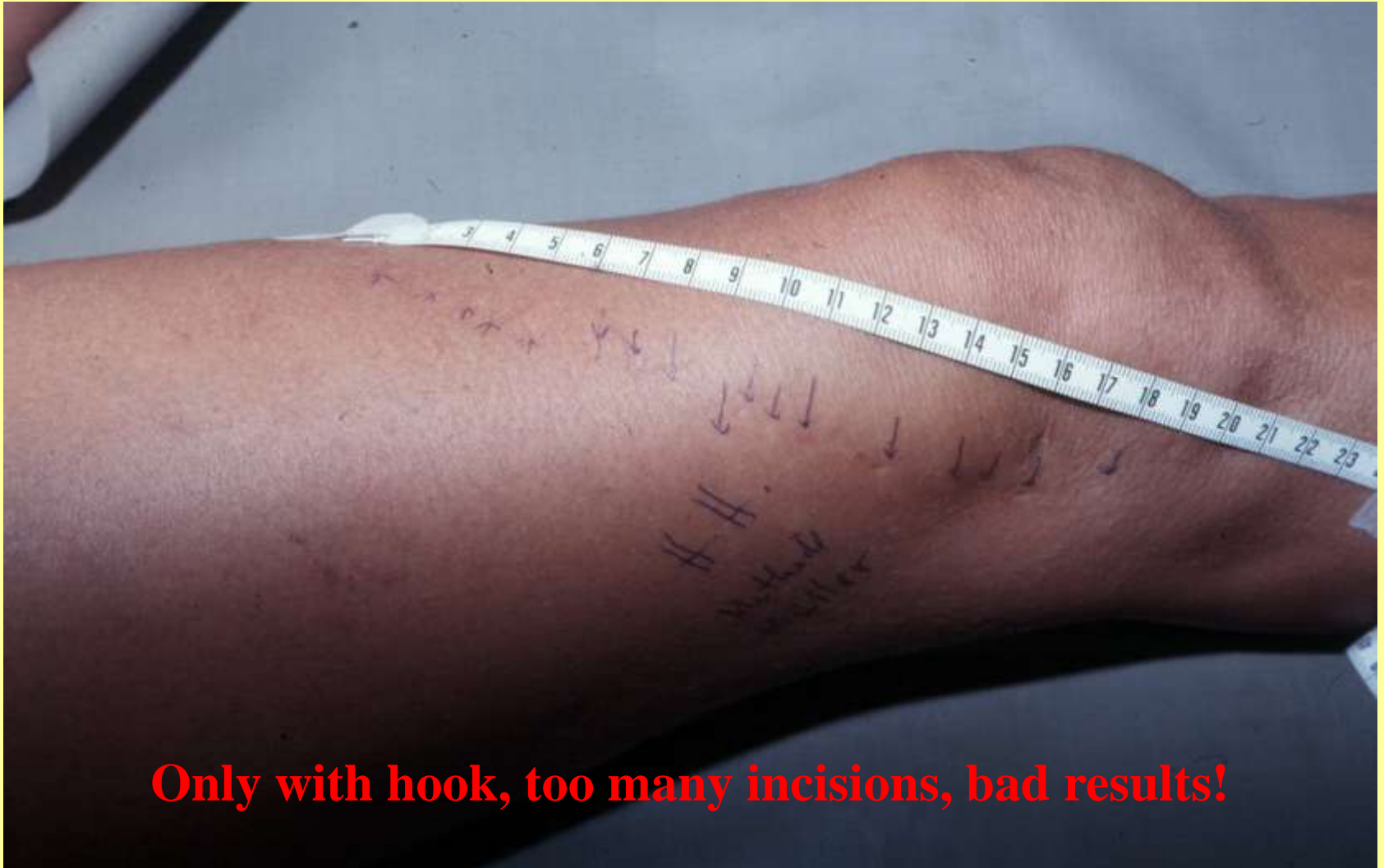


Minisurgery (Phlebectomy) has no cuts, only small intisions!
Using the spatula and hook: few incisions, good results !



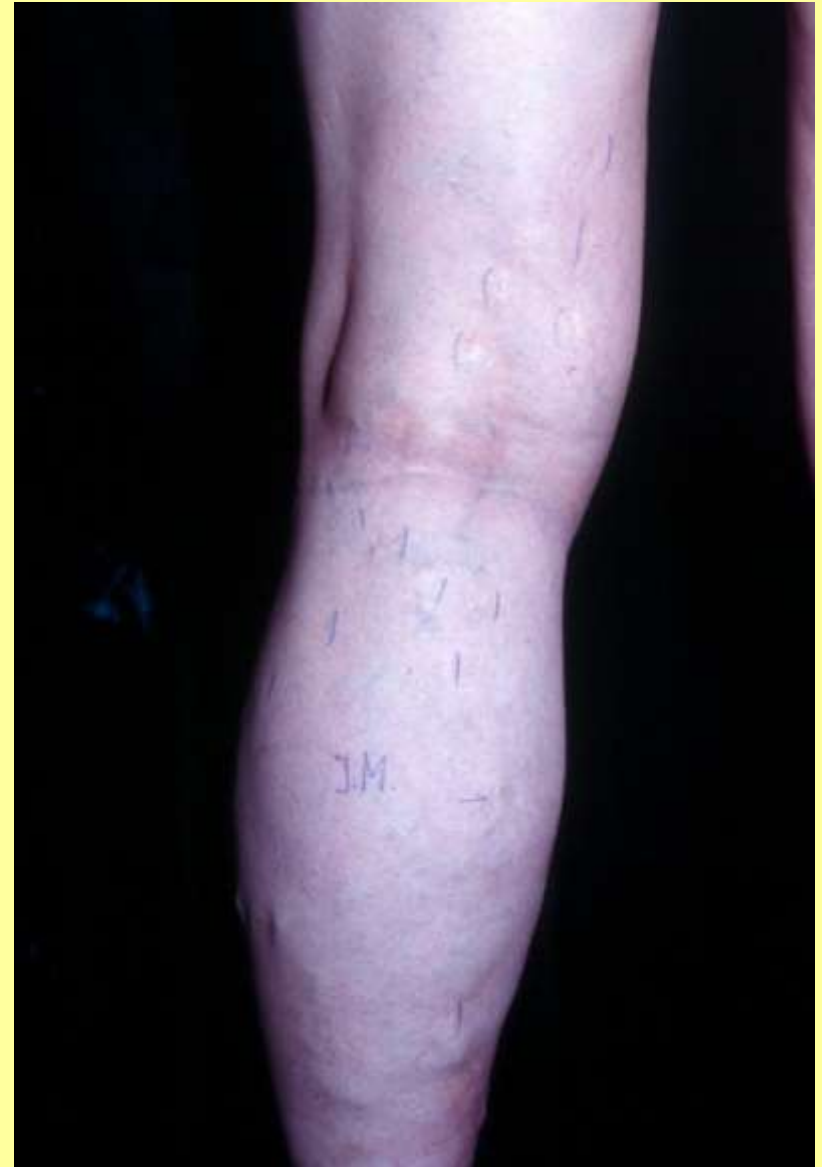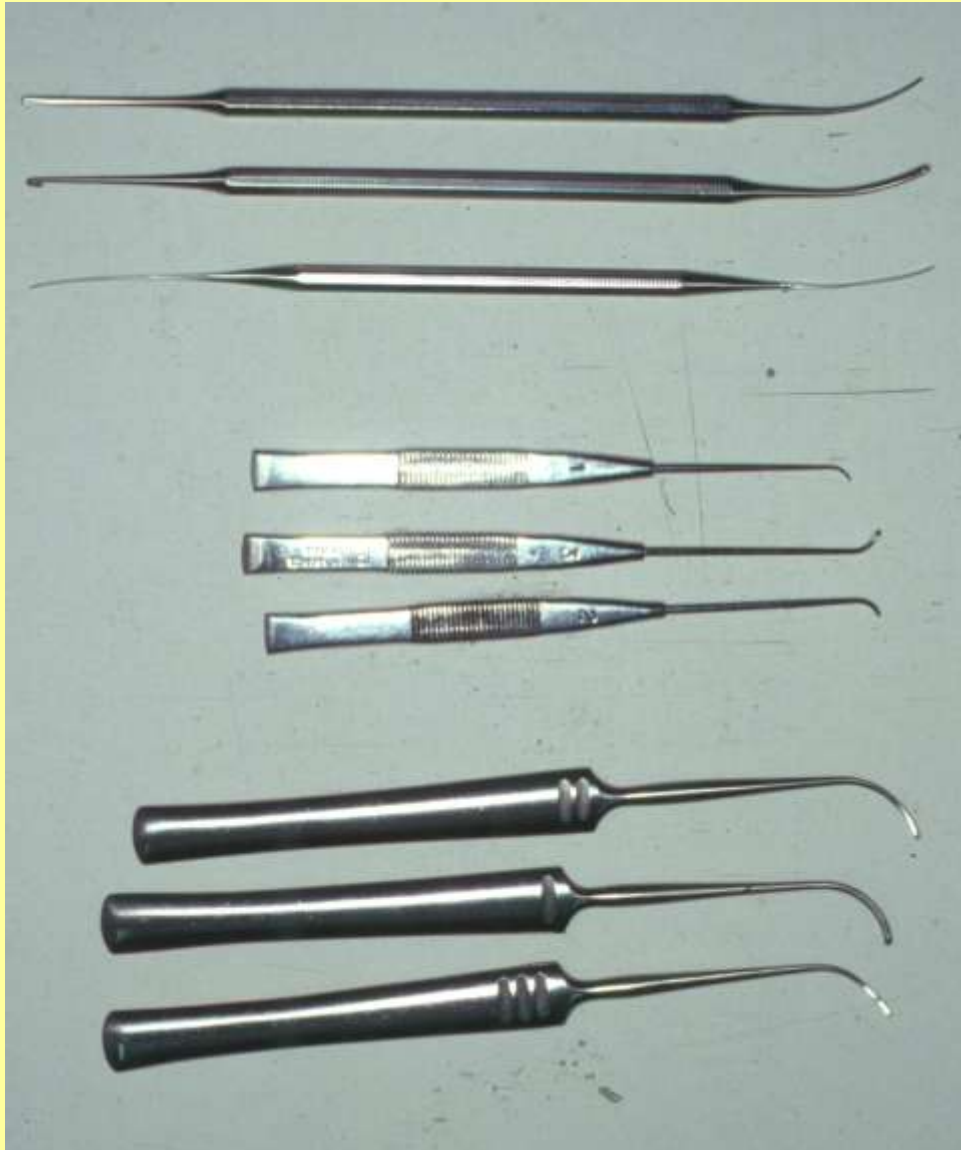One day after operation:

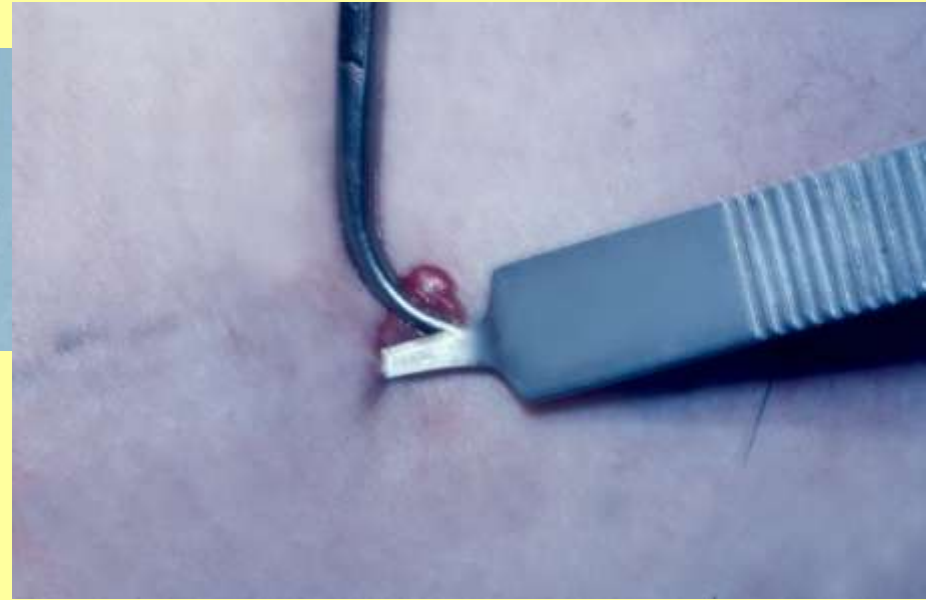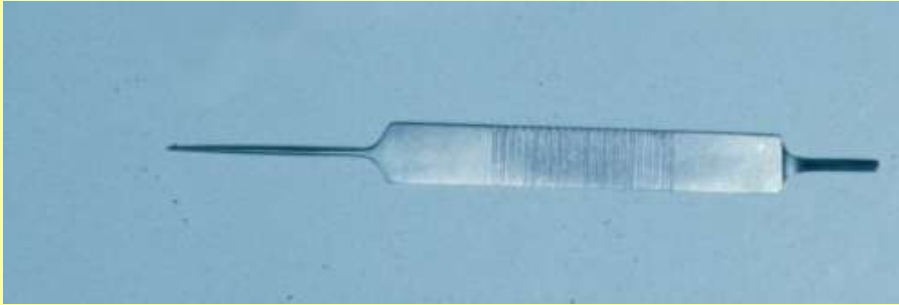**Many had thought of removing varicose veins through micro incisions.
Using more or less appropriate small hooks
it was tried to extract varicose veins
without considering that veins are fixed.**



Only with hook, too many incisions, bad results!

Therefore **neither the technique nor the instruments** were suitable
to get any further in this problem.
Only hook, minimosquito,scalpel 11: large incisions, poor results





The spatula is necessary to loosen the vein.

**Only the instrument of Prof. Degni (Sao Paulo)
had already the spatula but it was too short.**

He took my instruments.

**More than 30 years ago I developed a method for
which the company Aesculap provides the necessary instrumentation.**



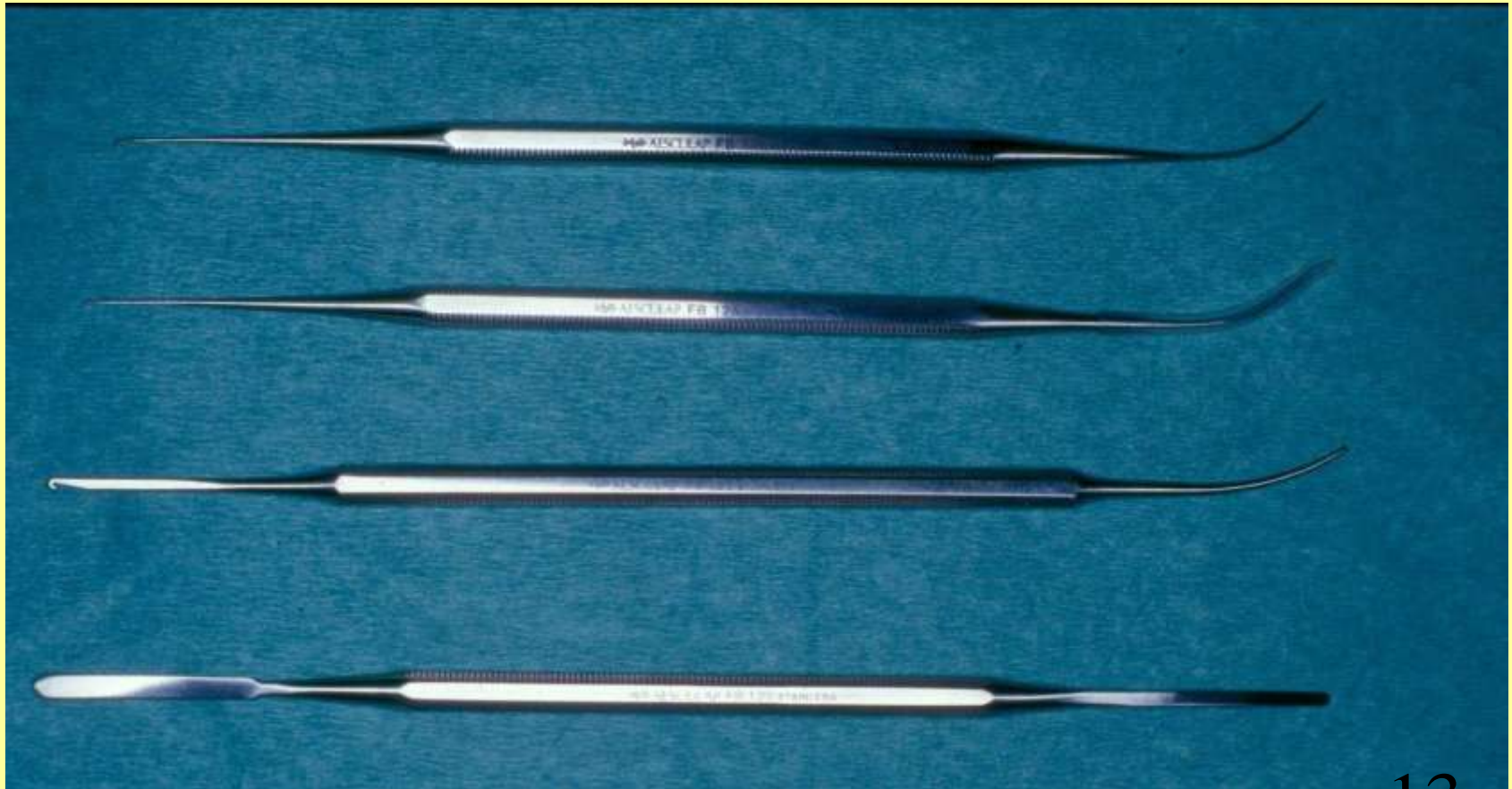**The Varady hook is well
known worldwide as
atraumatic hook. 12**

It is the first method **based on surgical principles** together with matching surgical instruments.

The Phlebextractor and the Phlebodissector

by which modern minisurgery of the varicose veins could be established.

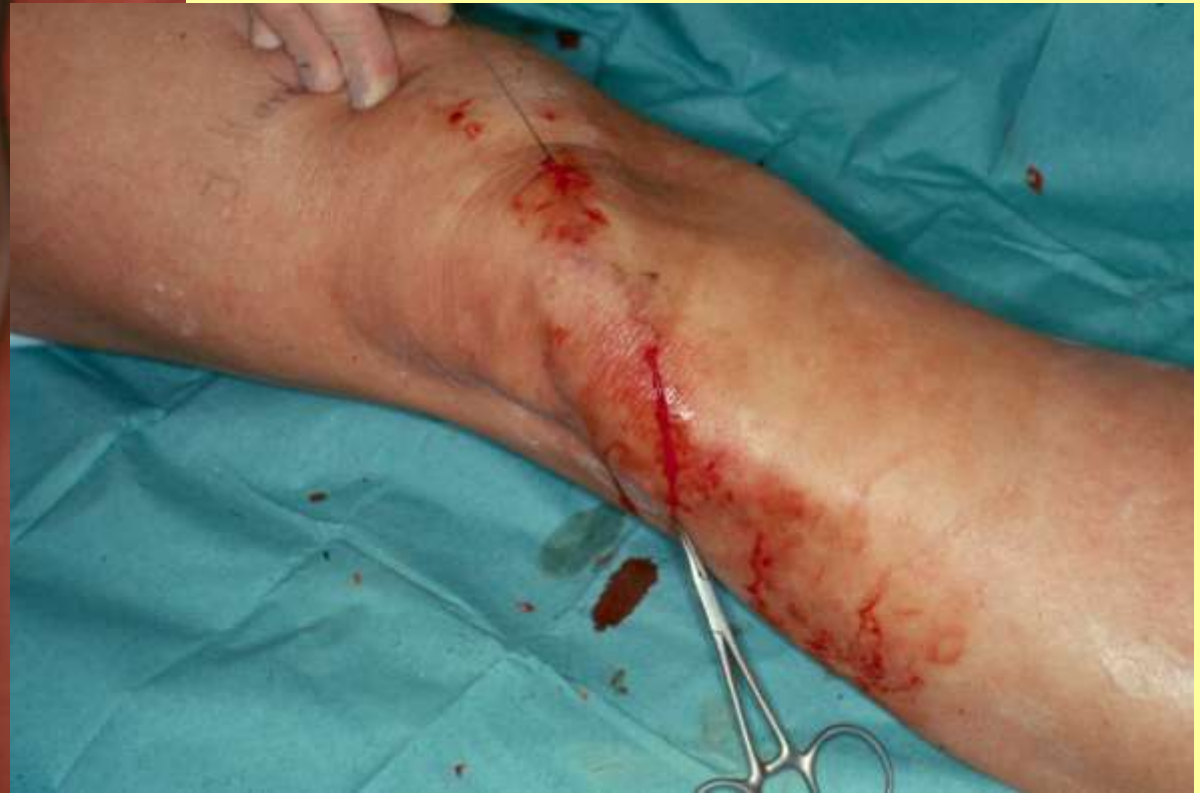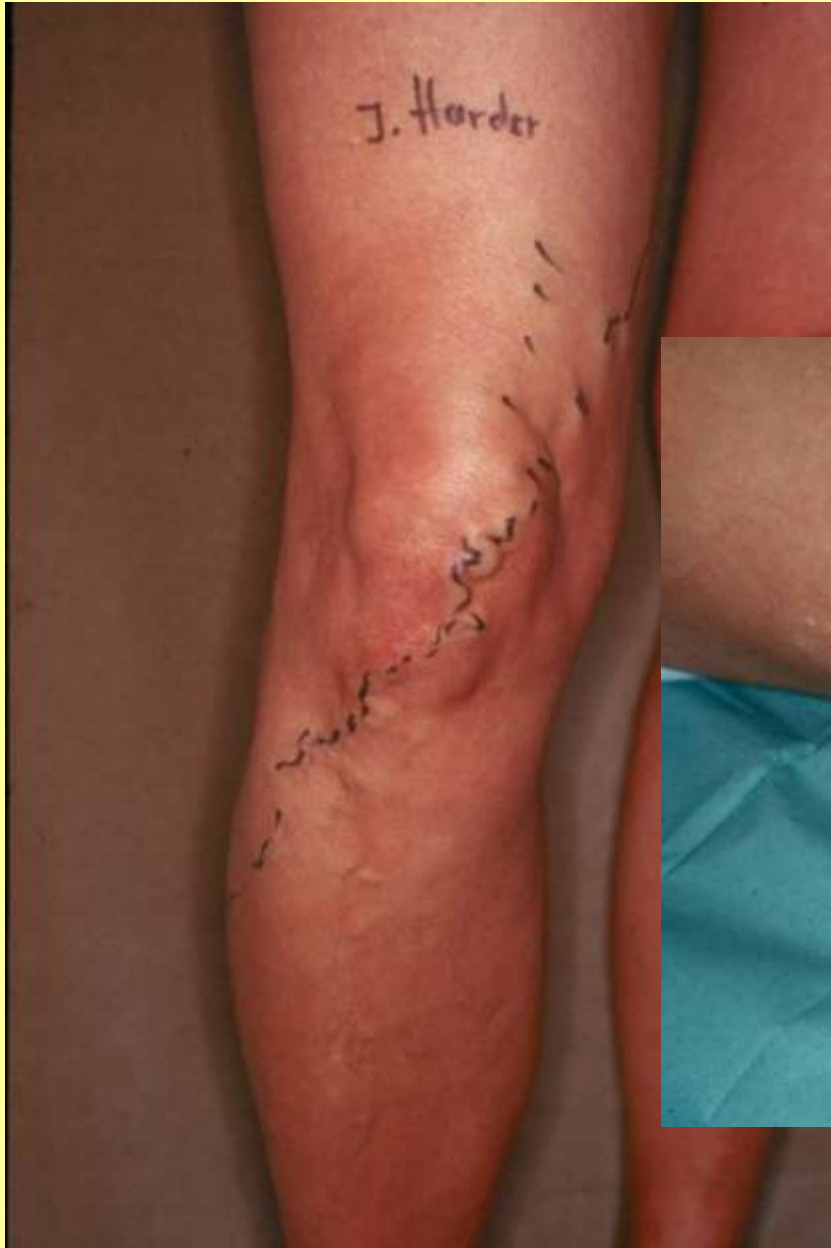Producer: Aesculap (Germany), Medicor (Hungary)



Ministriper for straight branch varizes.



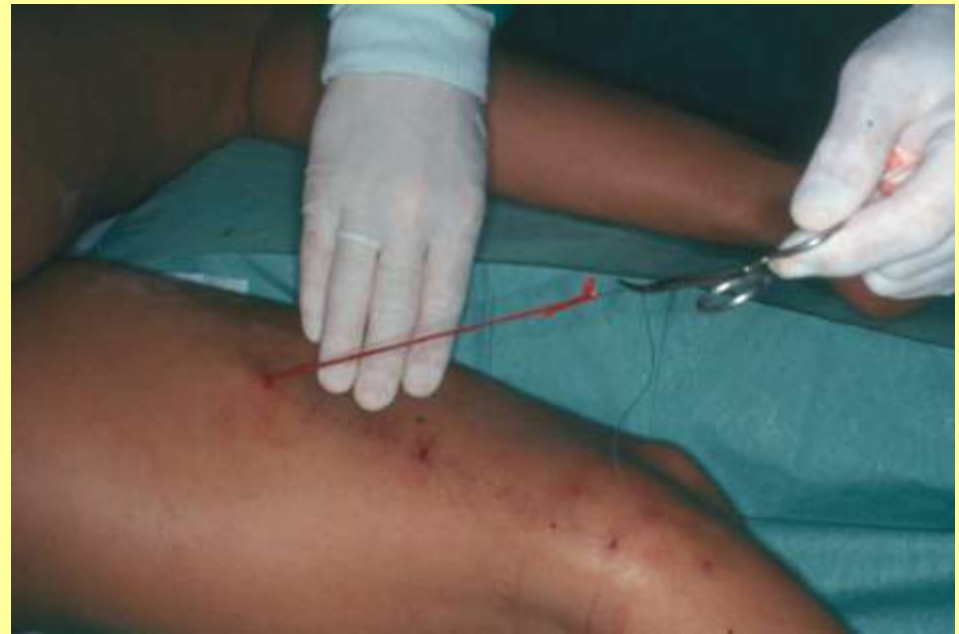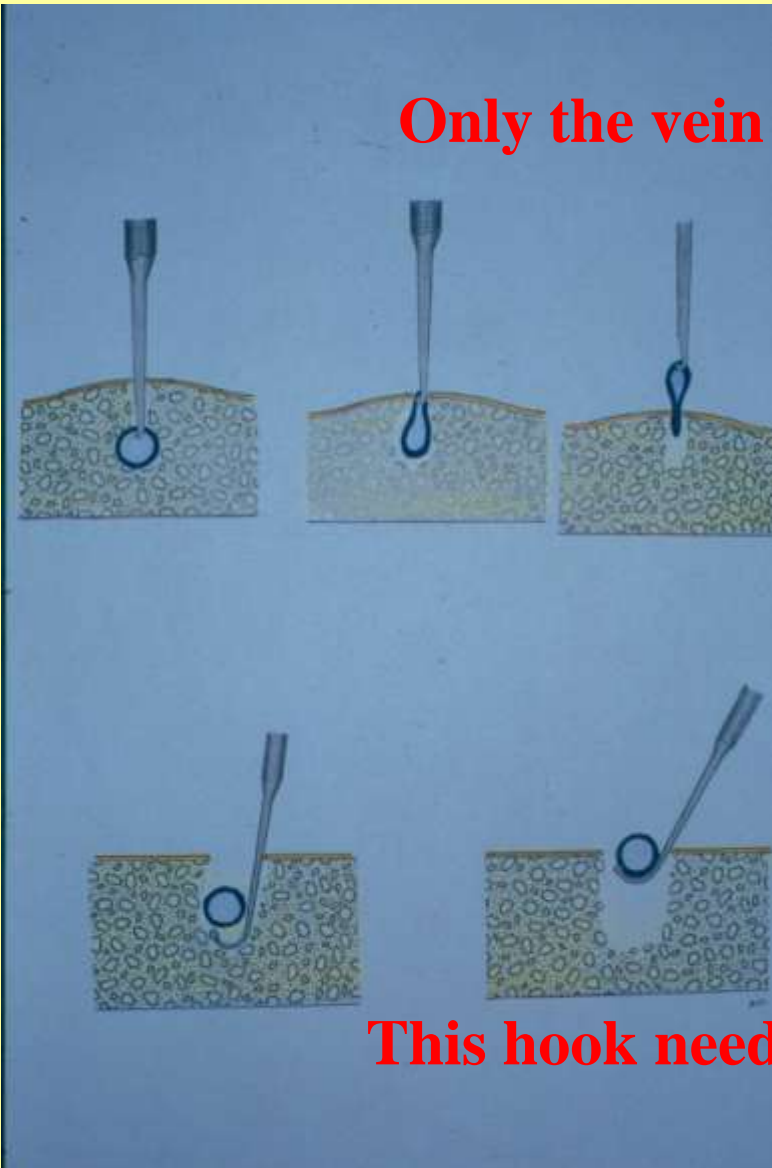
**Thus more than 30 years ago to specialists all over the world a
method was offered which cannot be imagined to be absent.**



Such method and instruments were able to gain their place in surgery.

They are accessible by a large number of colleagues and for the first time could be taken for serious as a true surgical technique.

Only the vein wall will be hooked.



This hook needs more incision.

Medicor



Aesculap





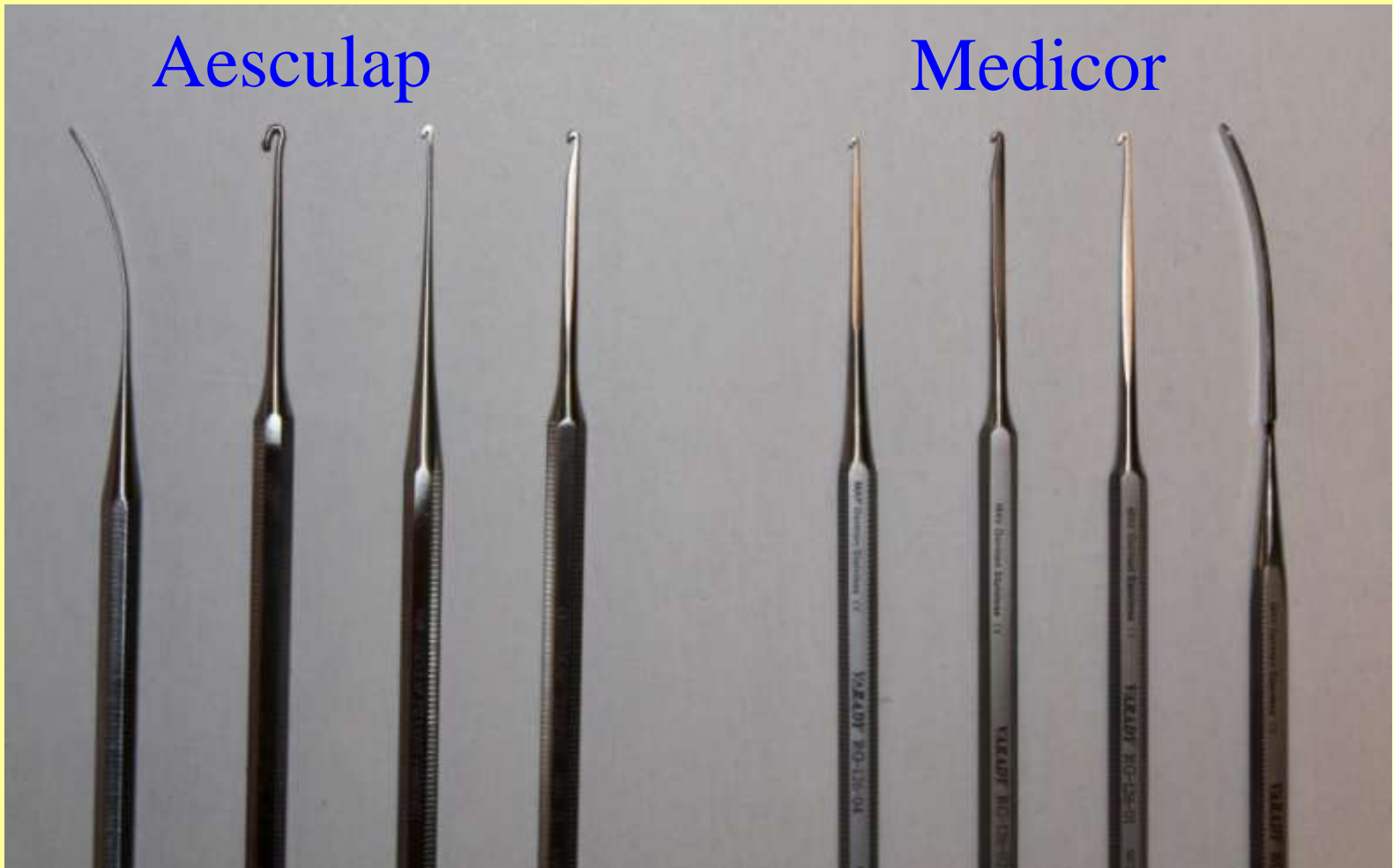
Ideal length to grasp the vein 17-19-19,5 cm

The handle part is hexagonal and grooved for an ideal handling.

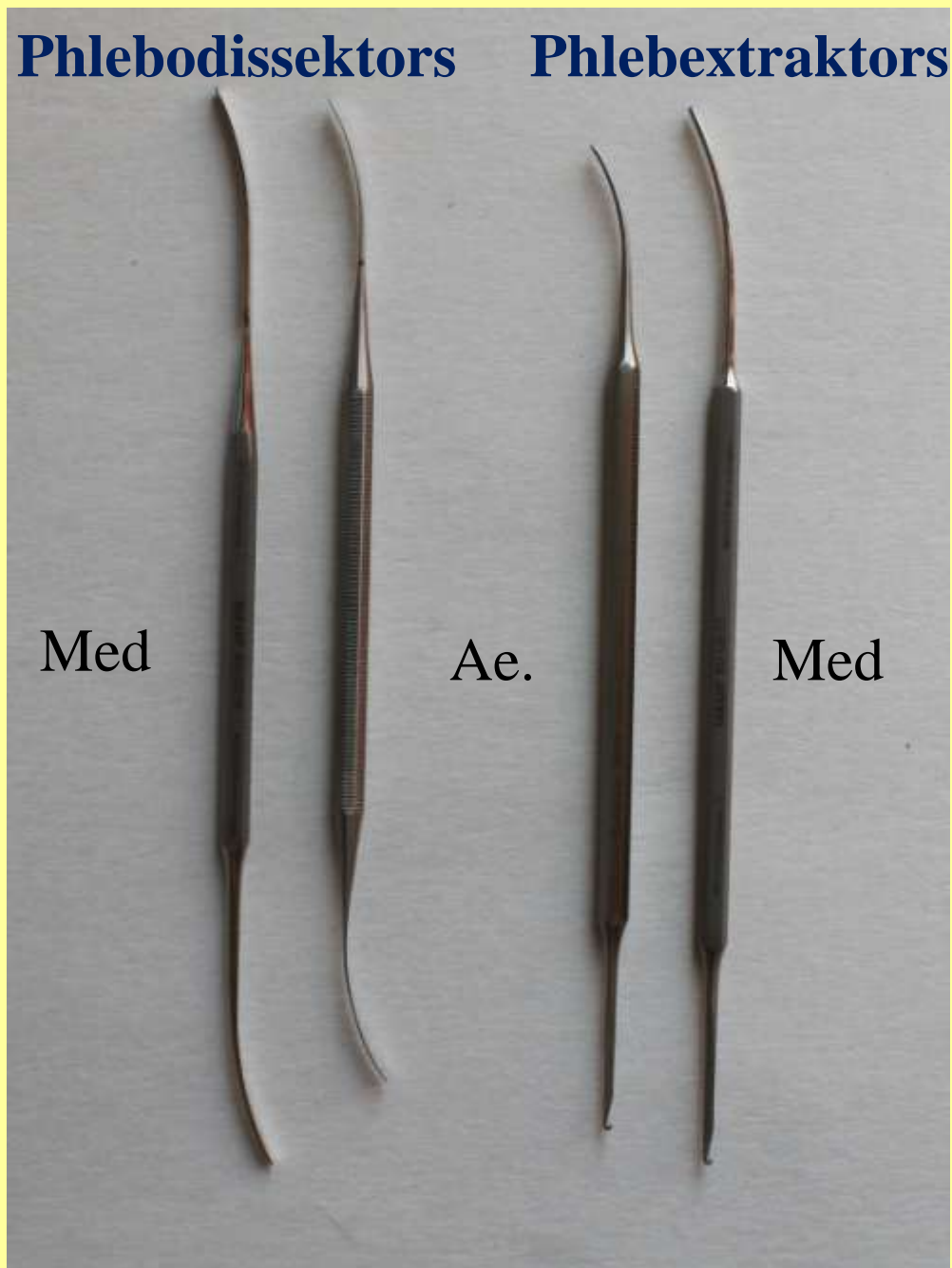
The hook is open opposite to the curve of the spatula, thus its position is always clear when inserted.

Aesculap

Medicor



The hook has an ideal size to be inserted through the small opening and a special shape which allows for grasping the venous wall without tearing it off.




The spatula of Phlebextraktor is rigid for good tissue penetration. Therefore is used first one.

The spatulas of Phlebodissektor are thin, flexible and longer. It permits a longer preparation range. We use these second one. Both of them have optimal curving.

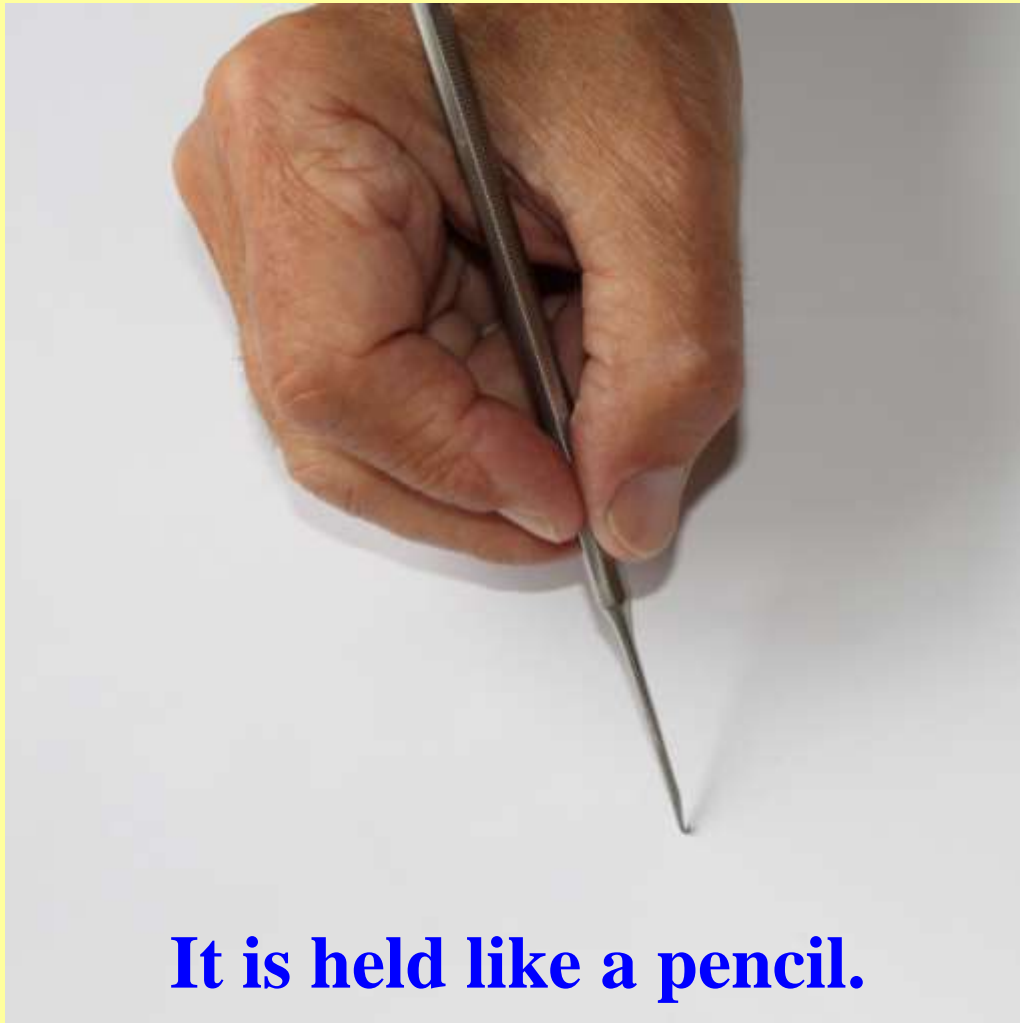


**Some years before the “CHIVA”
time I had made with this hook
by even the same method that I
left, and developed the
phlebectomy and mini surgery.**

**My discarded method and
instrument were as “CHIVA”
rediscovered, because the
Frenchs wasn’t able to read my
in German written works.**

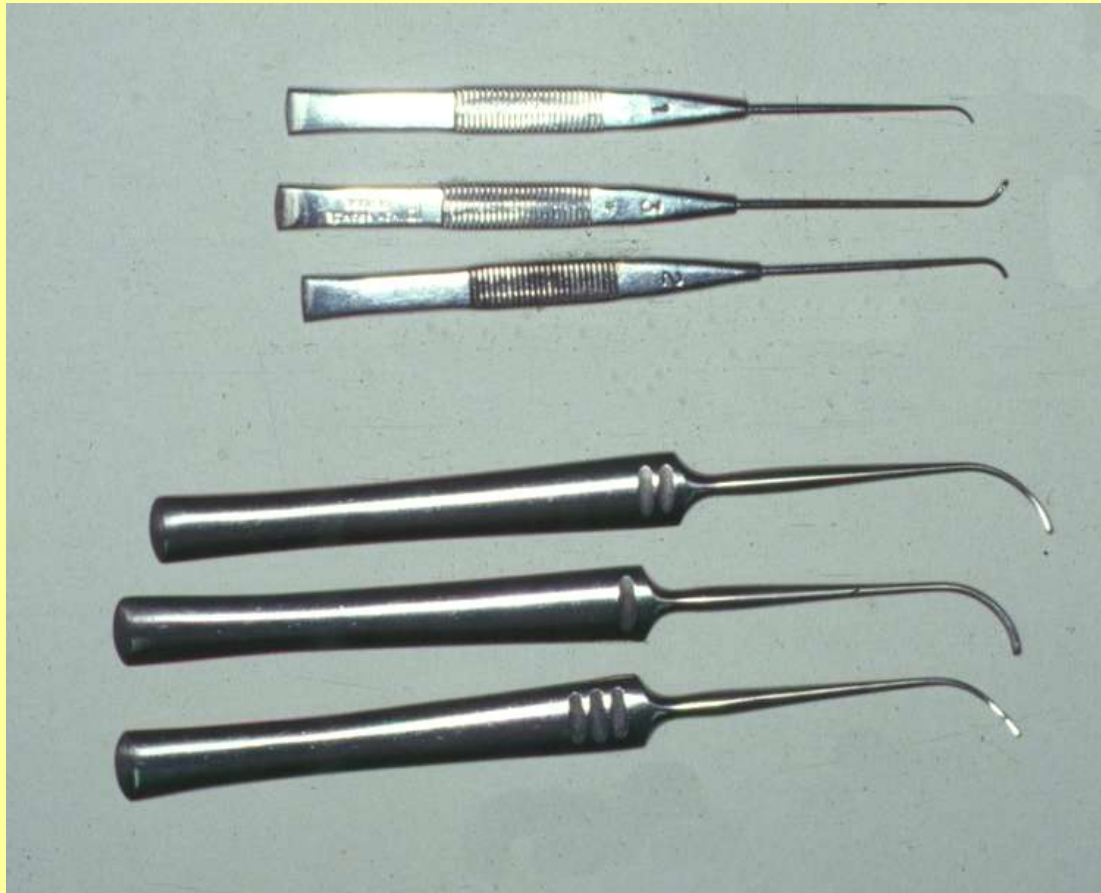


**My minisurgery instrument is
located on the middle finger.**



It is held like a pencil.

**Hold in the three fingers and
rotate with feeling the instrument.**



**If you use only hook,
you don't need
any expensive instrument.
That does an crochet hook.**



**These so-called "instruments" you hold with full hand,
thereby one feels the vein bad.**

Without spatula can one tear out only small pieces of veins.

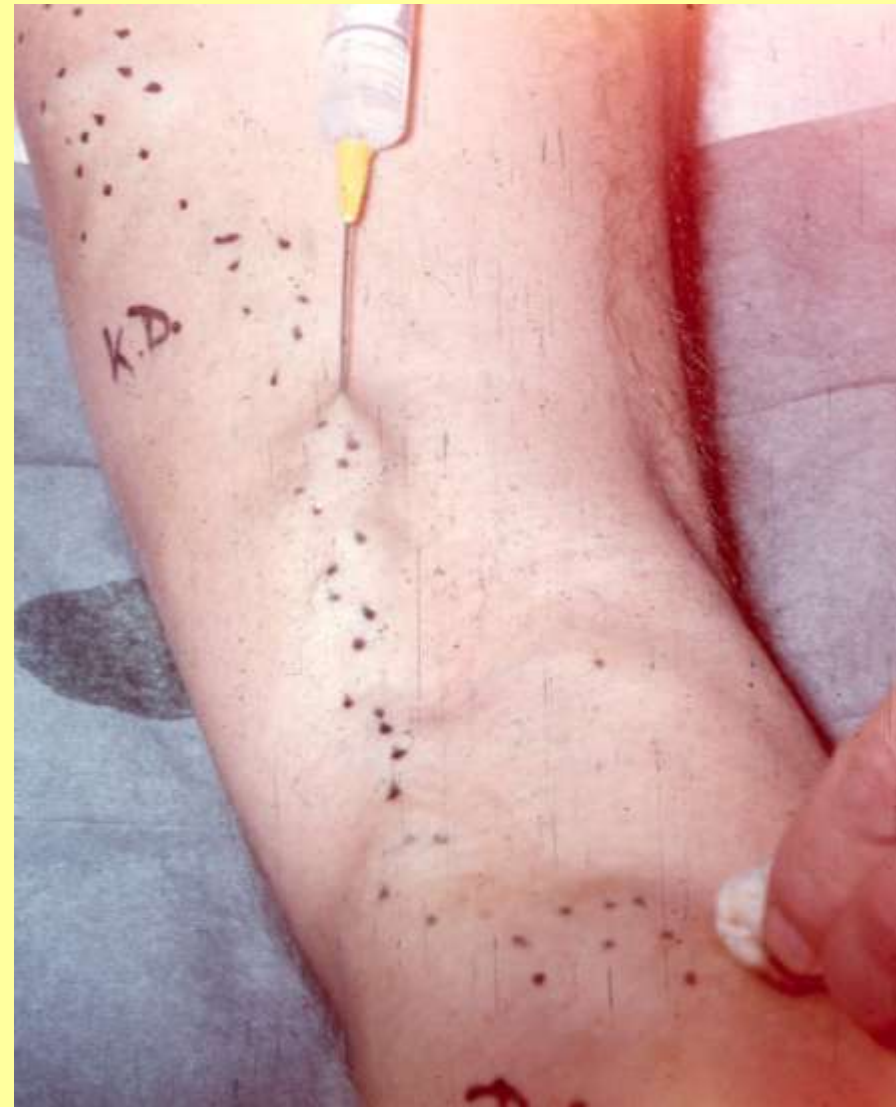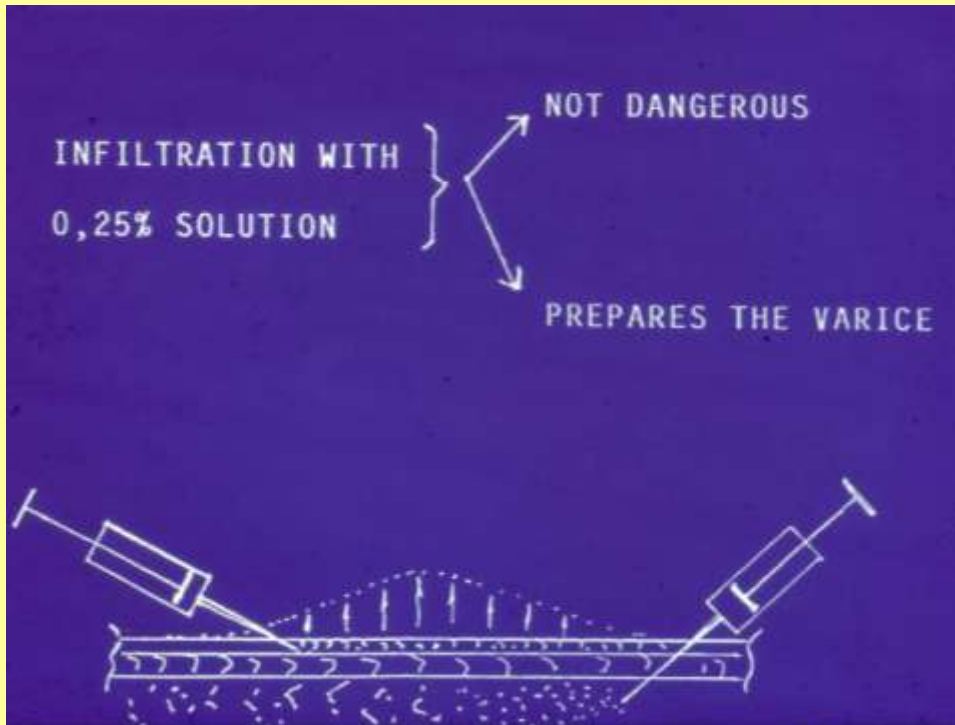
The minisurgery concept can mean to replace stripping or crossectomie, or as phlebectomy can be used to treat adequate veins, or in combination with other methods.

It is used since many years as an important therapeutic form of the varicose vein disease all over the world

It combines the advantages of surgery and sclerotherapy without having their disadvantages.

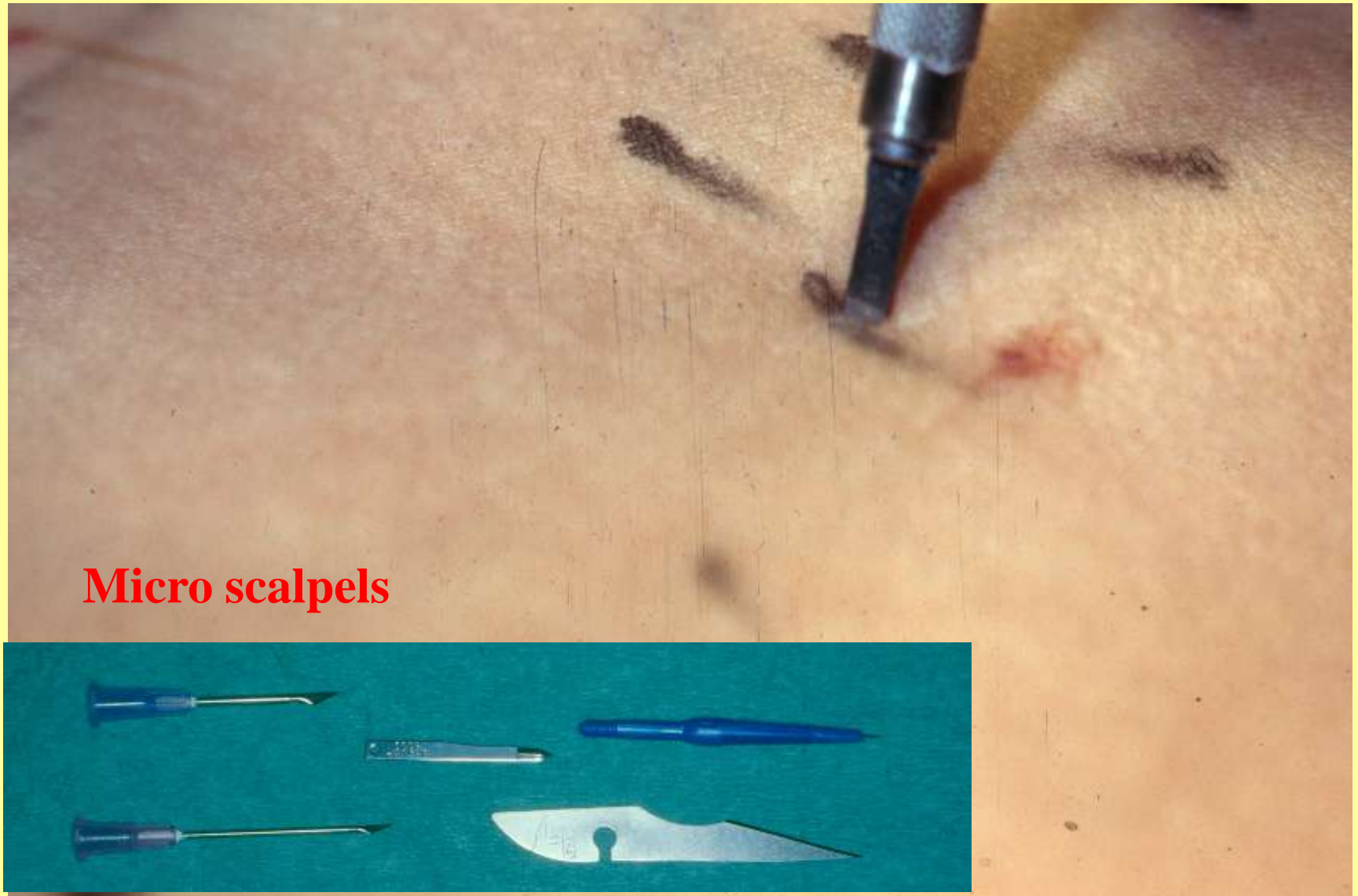
Local Anesthesia

Skin lift is well visible:



METHOD OF SURGERY

Tiny incisions are made with a special **micro scalpels** blade with which no big cuts can be made accidentally.



Micro scalpels

We use these Micro scalpels

Admix Needle

1,2 mm



1,6 mm



BAYHA 11



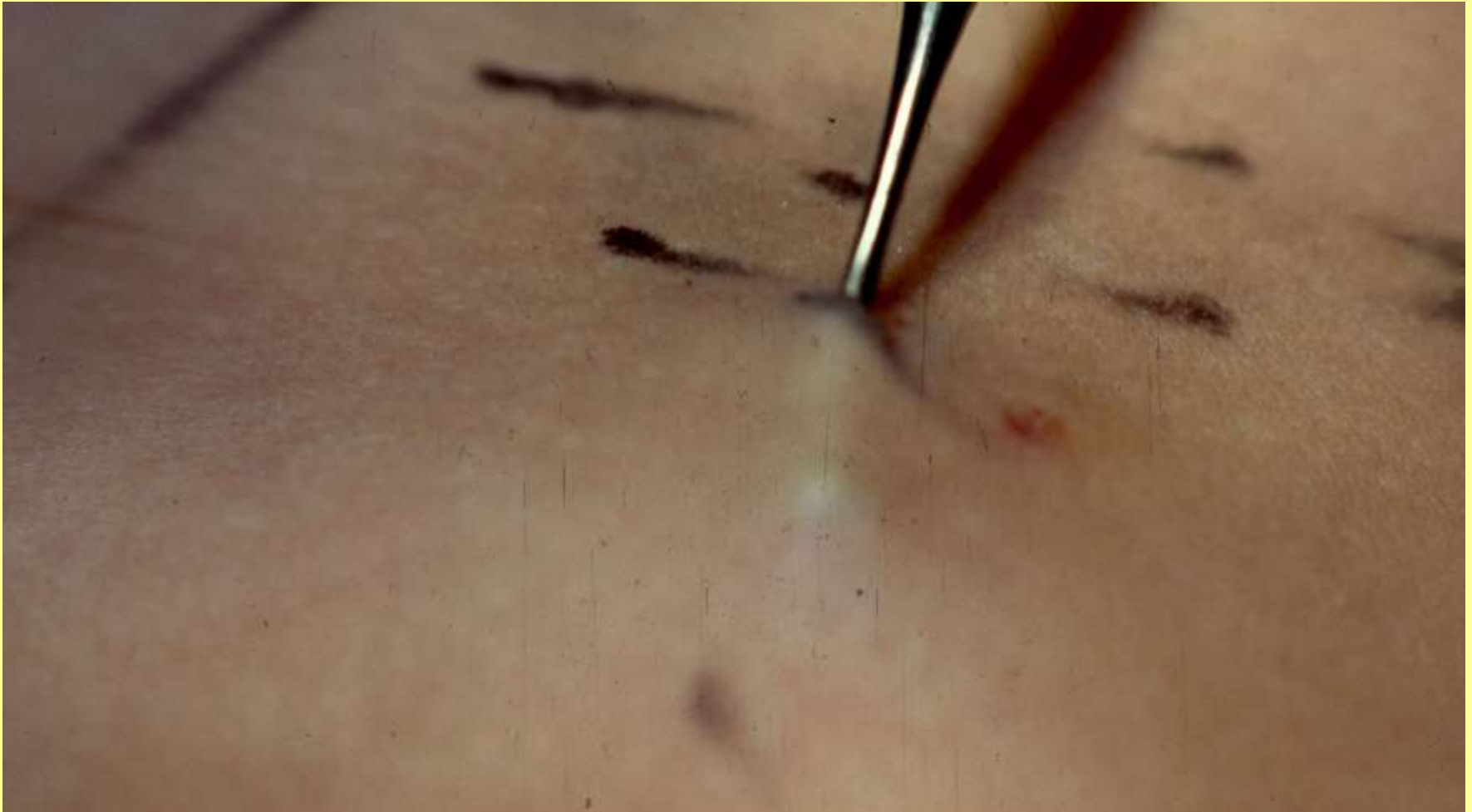
Scalpel 11 is too wide.

For minisurgery acc. Várady is inapplicably.



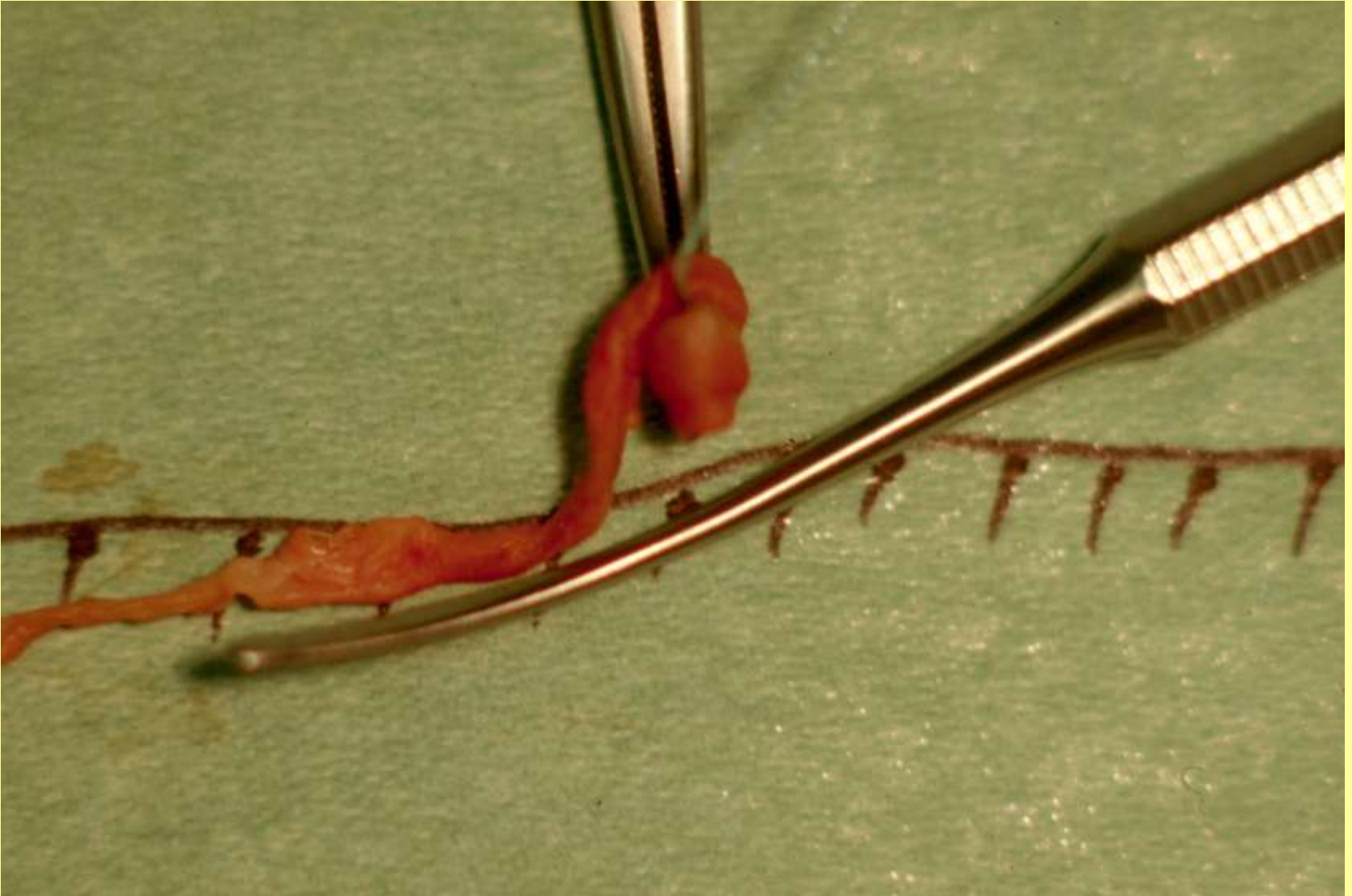
METHOD OF SURGERY

With using the **spatula end of the phlebextractor** veins are exposed in each direction of the incision.



The main **difference** between the old method and mine is the **use of the spatula**.

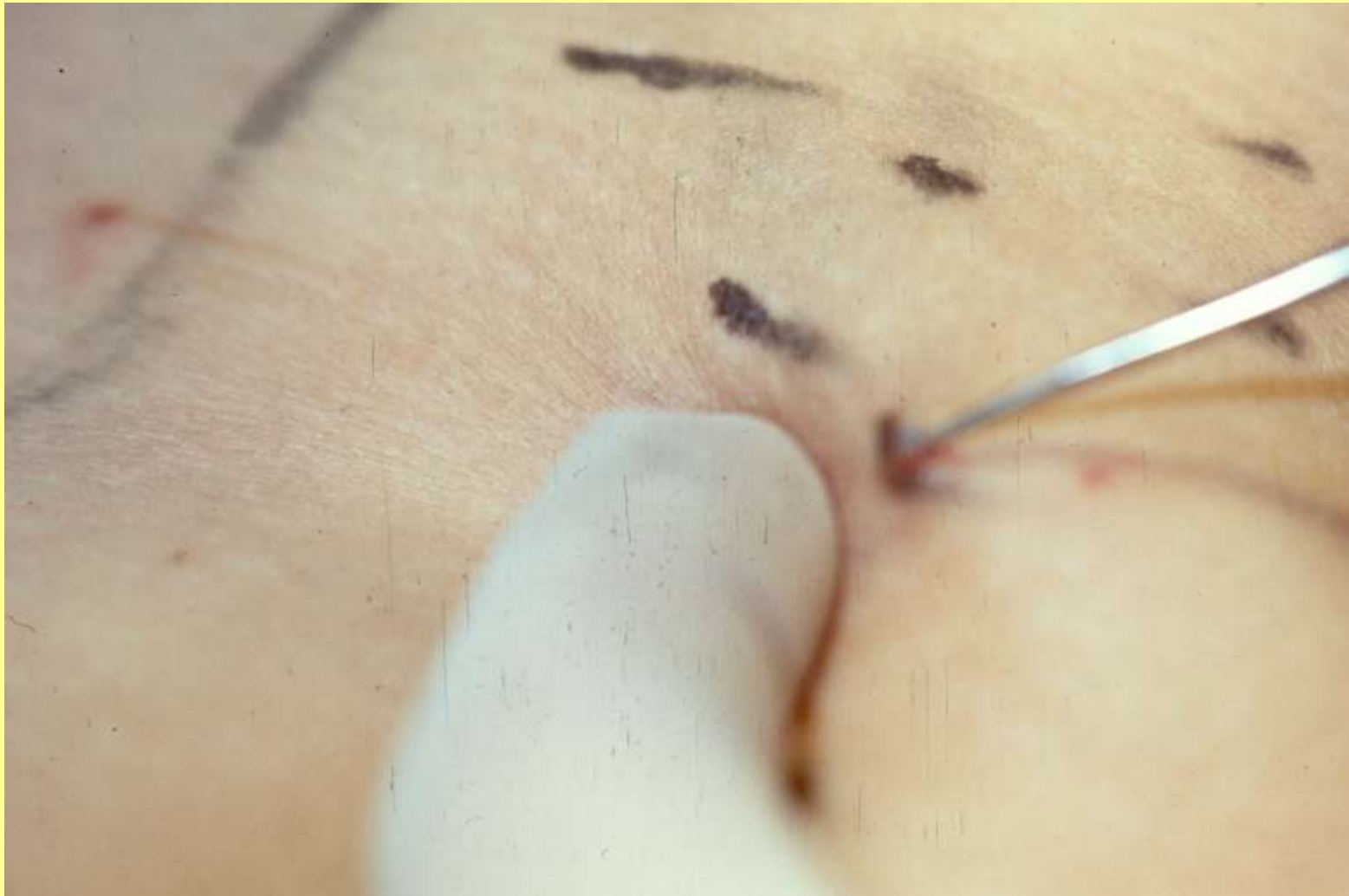**If you are using a spatula, then you are working with my method -
a surgeon will automatically recognize that varicose
veins cannot be removed without a spatula.**




METHOD OF SURGERY

Thereafter the instrument is **turned around** and with the opposite end (hook-ended) the vein is pulled out.

With your **fingers** you can imprint the skin in order to better feel and **find the vein**.

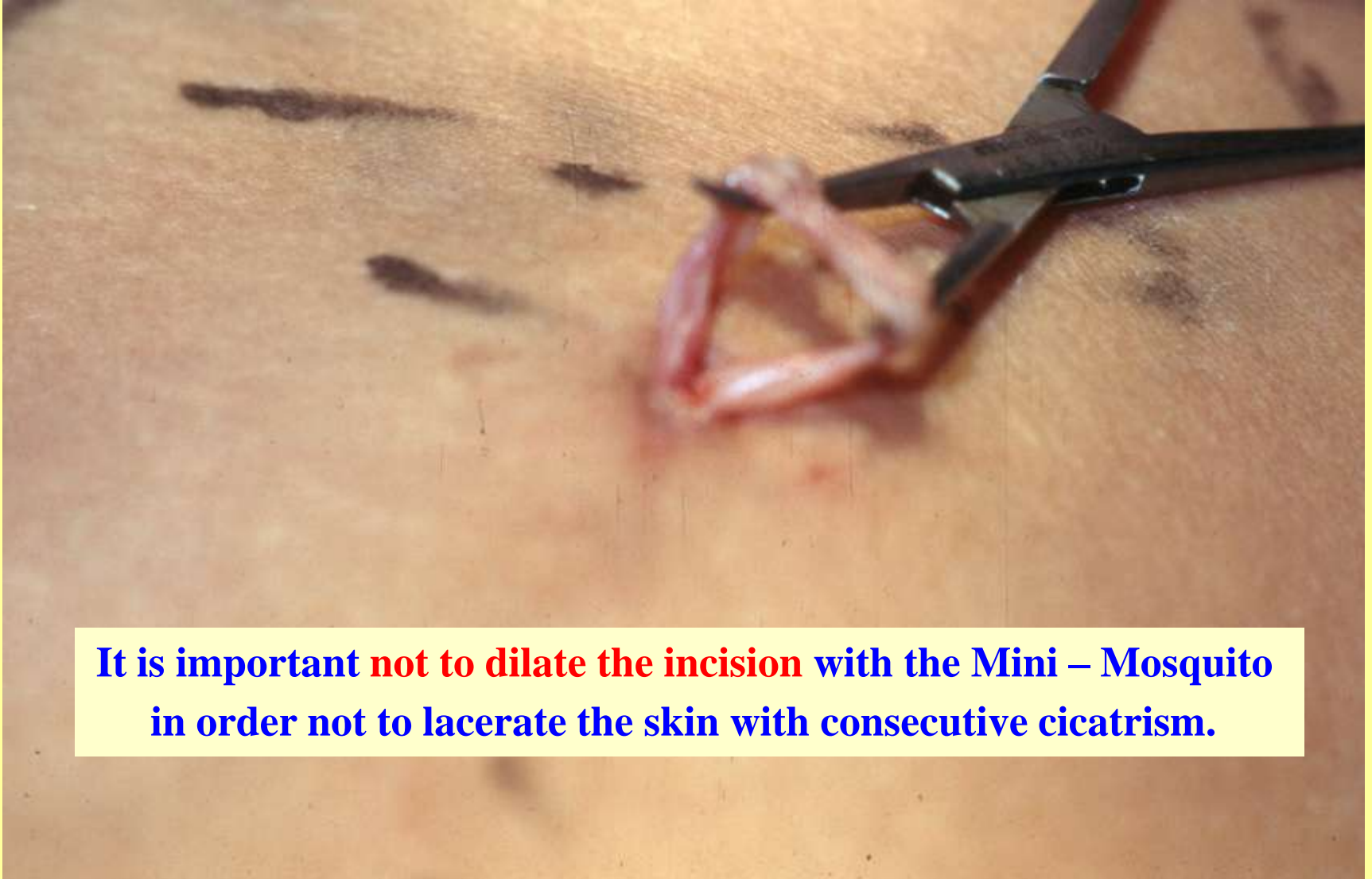

**The vein is between the finger tip and the
hook and so easy to palpate.**



METHOD OF SURGERY

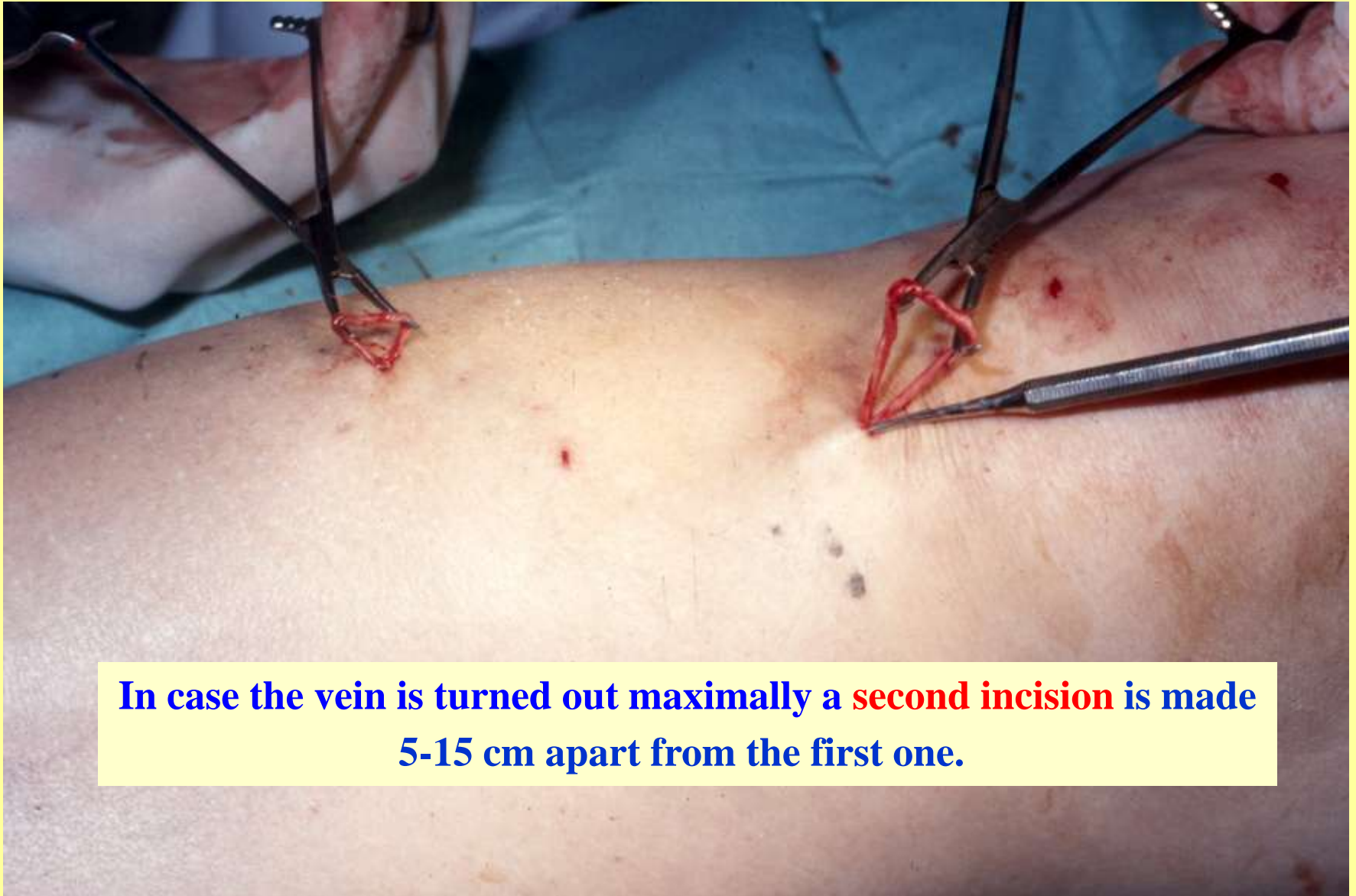The exposed vein is grasped with the Minimosquito forceps, followed then by ligation and separation.



It is important not to dilate the incision with the Mini – Mosquito in order not to lacerate the skin with consecutive cicatrism.

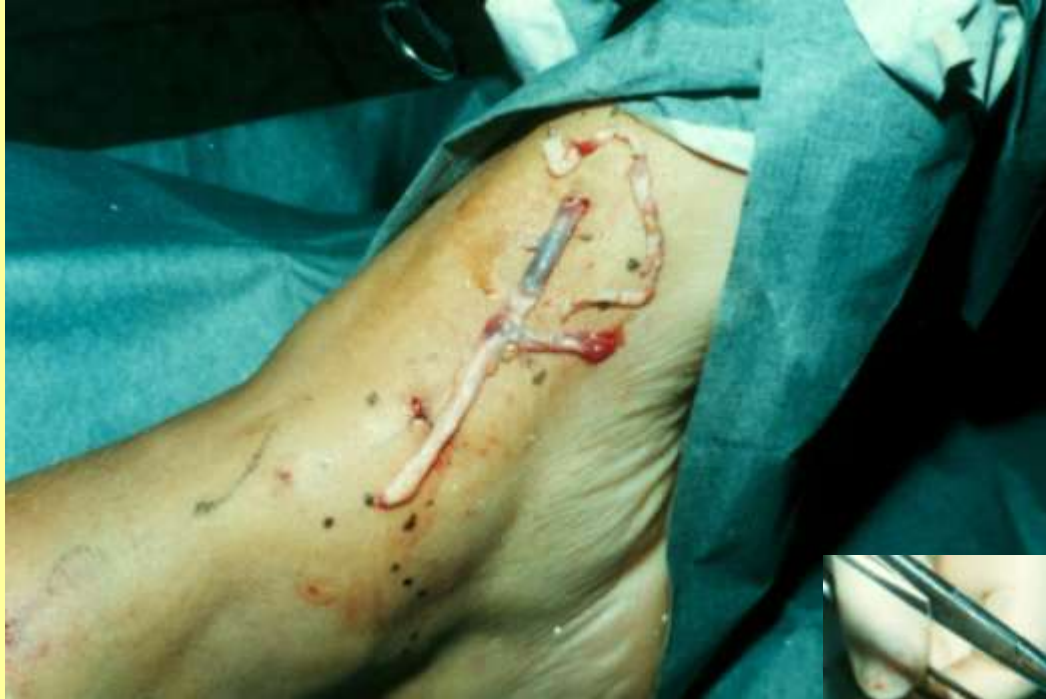METHOD OF SURGERY

Under continuous tension the vein is further prepared with the help of the **phlebextractor** or the **phlebodissector**.



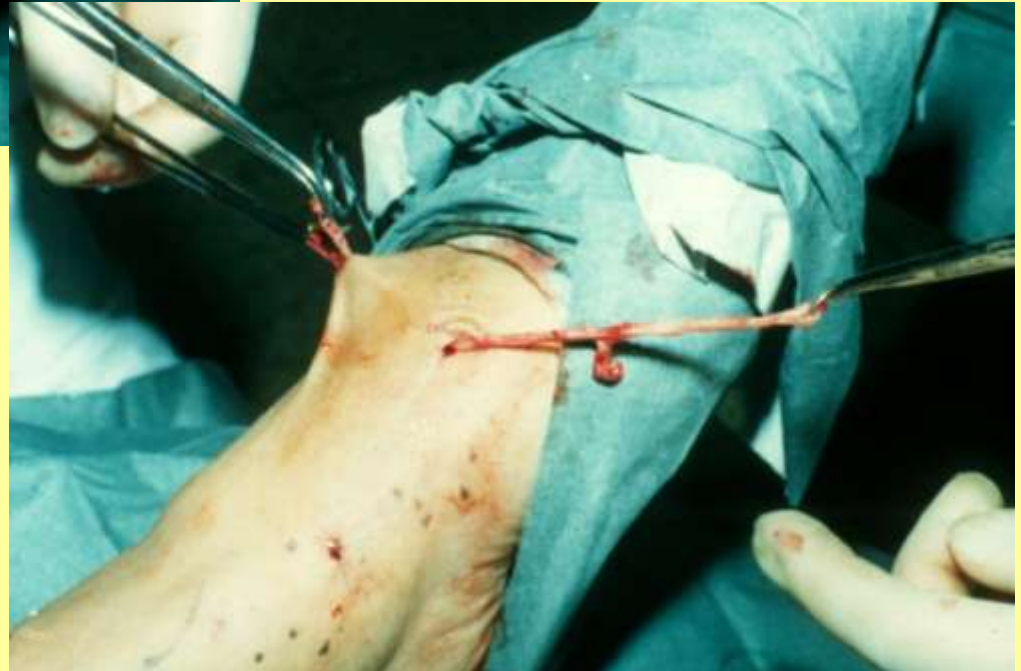In case the vein is turned out maximally a **second incision** is made 5-15 cm apart from the first one.

Extensive feet varicosis will be removed:

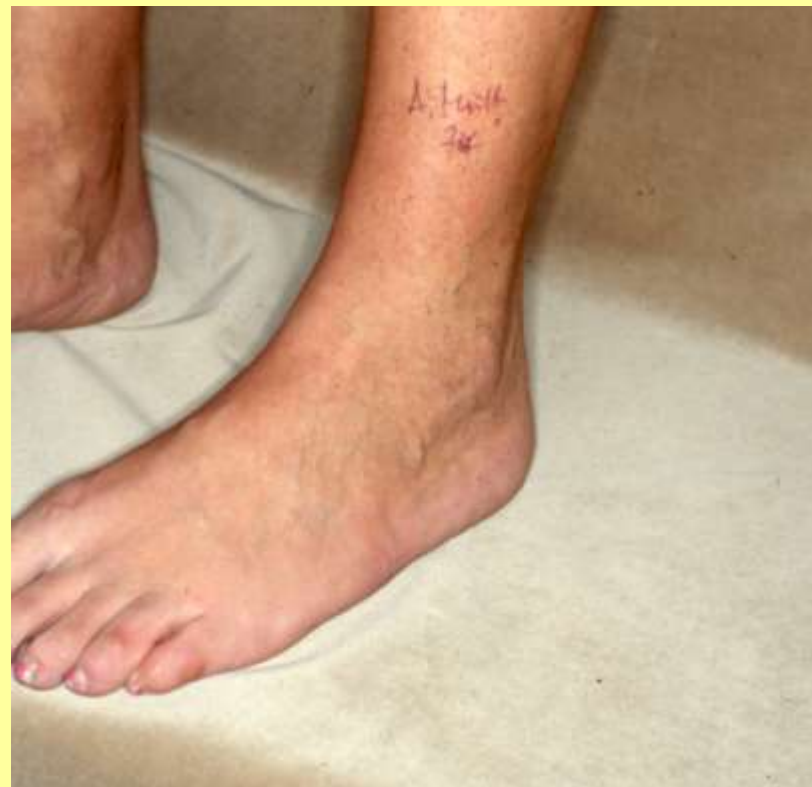
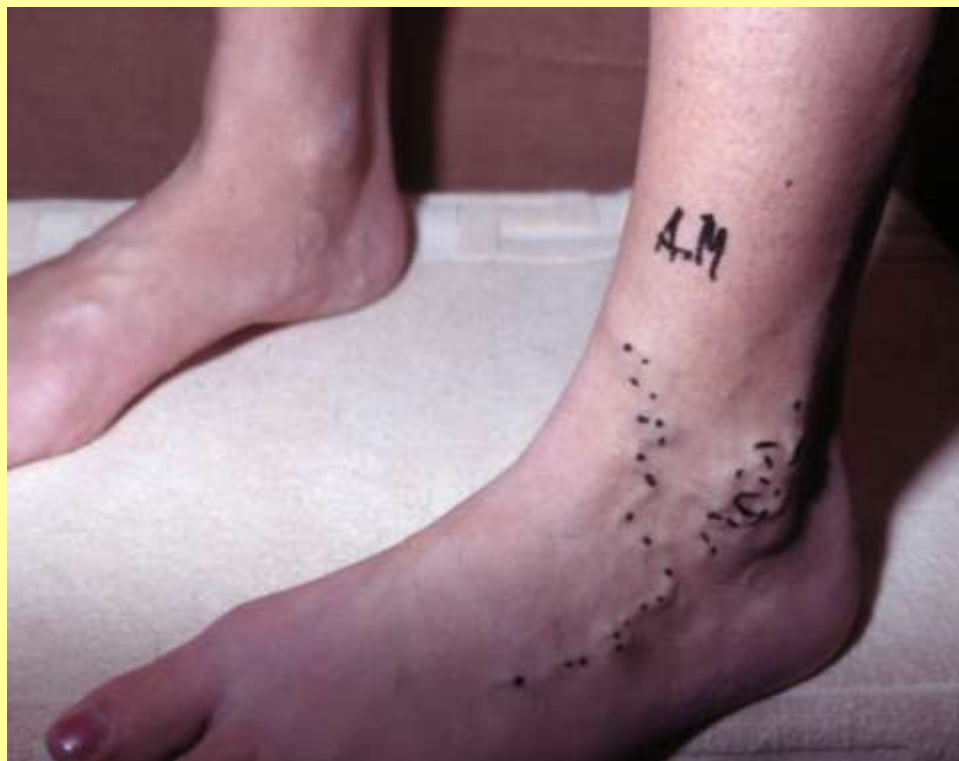
**Even in this region, the veins can
be removed without problems,
but carefully !**


This area optimal for Phlebectomy




At this area is the same solution:



To achieve good results, it is not necessary to use complicated and expensive methods, but to use your brain and the skills of your hands.





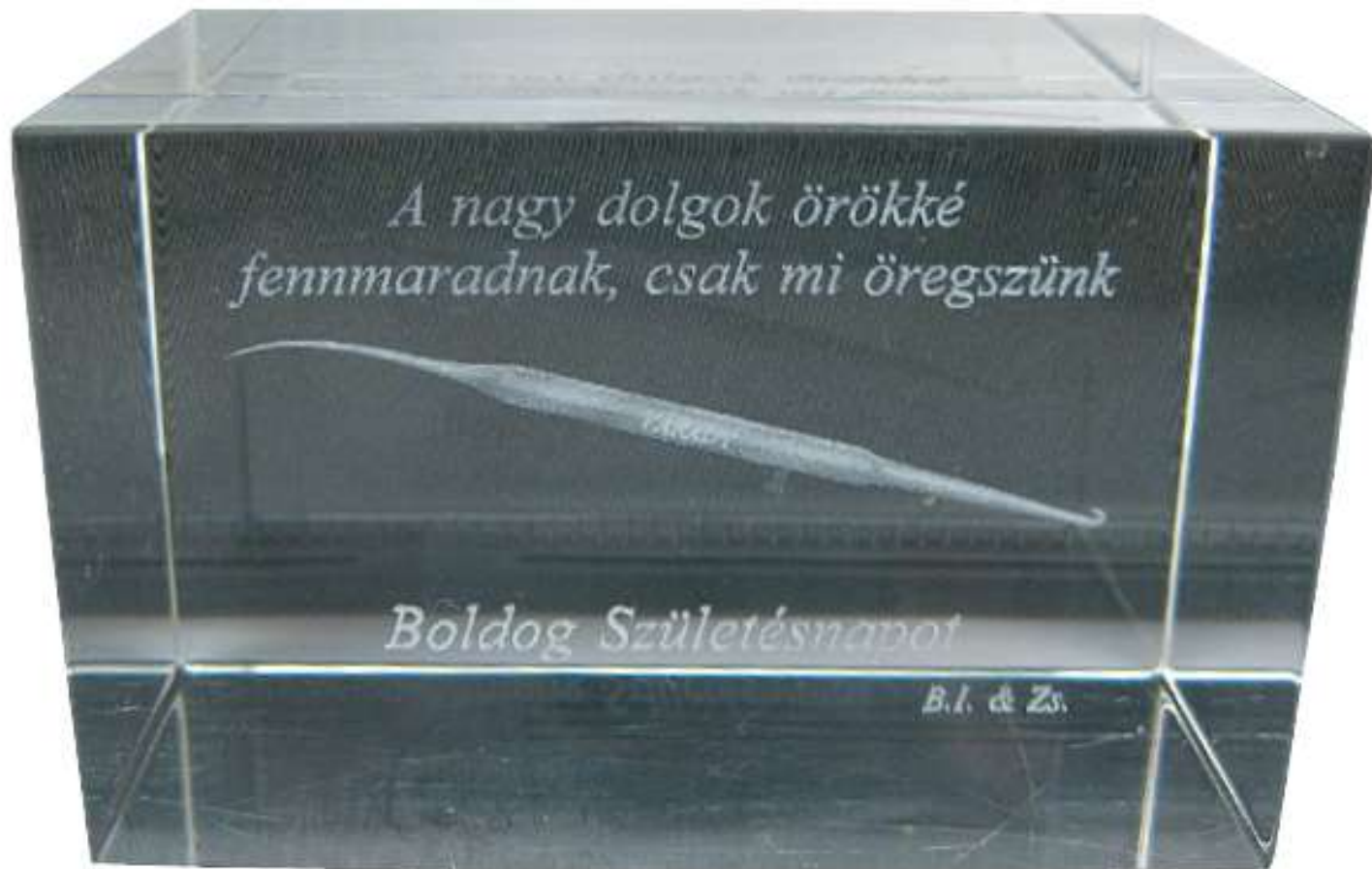**Von einer Künstlerin gezeichnete Minichirurgie,
Geschenk von Professor Brunner.**

By artist designed Minisurgery, Present from Professor Brunner.



**Vergoldeter Phlebextractor. Geschenk von Professor Brunner.
Gold-plated Phlebextractor. Present from Professor Brunner.**

Geburtstagsgeschenk von Professor Bihari.
Birthday present from Professor Bihari.



Die große Erfindungen bleiben immer nur wir werden alt.
The big things remain eternally, only we grow old.